ISAPS NEWS

OFFICIAL NEWS OF THE INTERNATIONAL SOCIETY OF AESTHETIC PLASTIC SURGERY

Volume 14 | Number 1

INSIDE

Harvard Survey

Global Perspectives: Abdominoplasty

BII Feature

BOARD OF DIRECTORS

PRESIDENT
Dirk Richter, MD, PhD
Wesseling, GERMANY
president@isaps.org

PRESIDENT-ELECT
Nazim Cerkes, MD, PhD
Istanbul, TURKEY
ncerkes@hotmail.com

FIRST VICE PRESIDENT
Lina Triana, MD
Cali, COLOMBIA
linatriana@drlinatriana.com

SECOND VICE PRESIDENT
Gianluca Campiglio, MD, PhD
Milan, ITALY
info@gianlucacampiglio.it

THIRD VICE PRESIDENT
Arturo Ramirez-Montanana, MD
Monterrey, MEXICO
docarturo@gmail.com

SECRETARY
Ivar van Heijningen, MD
Knokke-Heist, BELGIUM
i.vanheijningen@duinbergen-clinic.be

TREASURER
Kai-Uwe Schlaudraff, MD, FEBOPRAS
Geneva, SWITZERLAND
schlaudraff@concept-clinic.ch

HISTORIAN
Peter Scott, MD
Johannesburg, SOUTH AFRICA
peters@cinet.co.za

PARLIAMENTARIAN
Tim Papadopoulos, MD
Sydney, AUSTRALIA
drtim@drtim.com.au

EDUCATION COUNCIL CHAIR
Vakis Kontoes, MD, PhD
Athens, GREECE
vakiskont@gmail.com

EDUCATION COUNCIL VICE CHAIR
Ozan Sozer, MD
El Paso, Texas, US
doctor@elpasoplasticsurgery.com

NATIONAL SECRETARIES CHAIR
Michel Rouif, MD
Tours, FRANCE
michel.rouif@wanadoo.fr

PAST PRESIDENT
Renato Saltz MD, FACS
Salt Lake City, Utah, US
rsaltz@saltzplasticsurgery.com

TRUSTEES
Fabian Cortinas MD
Buenos Aires, ARGENTINA
fabiancortinas@gmail.com

Nina Naidu, MD, FACS
New York, New York, US
drnaidu@naiduplasticsurgery.com

EXECUTIVE DIRECTOR
Catherine Foss
Hanover, New Hampshire, US
isaps@isaps.org

No. 1
VOLUME 14

CONTENTS

Message from the Editor	3
Message from the President	4
Global Alliance	7
Education Council Update	9
Members Write	10
Course Reports	11
Visiting Professor Programs	16
Features: BII	19
Global Accreditation Update	22
Patient Safety	23
Journal Update	29
Global Perspectives	30
Case Study	68
Surgical Marking	70
Member Spotlight	71
History	73
New Members	77
Meetings Calendar	79

MESSAGE FROM
the Editor

Dear Colleagues,

I hope that this issue finds you and your families in good health. By now we are all aware of the global pandemic of coronavirus COVID-19 that will undoubtedly affect all of our lives and practices in some fashion before it is controlled. Be safe and be well.

2020 has already seen movement in the plastic surgery world as well. In the United States, there has been discussion within the Food and Drug Administration (FDA) concerning the creation of an ICD-10 diagnosis for Breast Implant Illness (BII). While the initial hearing has been postponed, this is an item that could potentially affect all ISAPS members, as creation of a diagnosis code implies a clear disease, which has not yet been established. For a more detailed discussion of this critical topic, please read the Feature article included in this issue.

This issue's focus topic is abdominoplasty and we received a large number of remarkable articles that introduce variations on standard techniques, as well as those which present new ways of approaching this very popular procedure. Each article is unique and adds pearls to our knowledge of this very common procedure. A few of the standout articles include those by Dr. Elizabeth Hall-Findlay, who delivers a highly practical article based on her extensive experience, and a case study by Dr. Juan Esteban Sierra Mejia who used abdominoplasty as a means of scar revision on a difficult case. I would especially like to commend Dr. Maria Isabel Cadena Rios from Colombia who presented an outstanding talk in Miami Beach at the ISAPS Congress in 2018. She was kind enough to write up her technique at my insistence, and it is presented here. Dr. Cadena emphasizes the importance of a 360° approach to abdominoplasty, and her amazing results simply speak for themselves.

Our next issue will feature breast augmentation and I look forward to the many articles that I anticipate will be submitted on this topic. We would love to see articles covering the full range of breast enhancement techniques, including implants, fat grafting, and revision. Please send them to isaps@isaps.org

Finally, as many of you already know, our wonderful Executive Director, Catherine Foss, will be retiring at the end of this year. In addition to pouring heart and soul into ISAPS for the past twenty-two years, she is the Managing Editor of this newsletter, and these issues frankly would not be in your hands without her. On a personal note, she has also become a close friend and ally, and I will truly miss her support and humor. Please reach out to her at catherine@conmx.net to send your best wishes.

I look forward to your feedback and suggestions as we continue to improve upon your newsletter. Thank you for all you do for ISAPS.



Nina Naidu, MD, FACS - United States
Editor-in-Chief

WE HAVE ALSO EVALUATED OUR MEMBER SURVEY VERY METICULOUSLY THIS YEAR AND ARE PARTICULARLY PLEASED THAT THE SATISFACTION WITH OUR SOCIETY HAS AGAIN INCREASED.

MESSAGE FROM the President

Dear Friends,

The year has gotten off to a turbulent start and we have just begun with a new face in membership services. Stephanie King has been hired to meet the growing needs of our members which has become more demanding due to the ever-increasing number of members. She works in our London office and is responsible for all your membership queries. Welcome Stephanie!

Our e-learning platform, ISAPS MedOne, is on the road to success and now has twice as many users within one year. In the meantime, almost 70 valuable books on all areas of aesthetic surgery are available online with a value of about US$17,000. The 3rd brand new edition of "The Art of Aesthetic Surgery" by Foad Nahai will be available in three volumes in the library with an equivalent value of US$1200.00 in addition to almost 1500 videos and many questions to prepare for your board certification.

The biggest IT modernization in the history of ISAPS has been completed and initially still has some teething troubles to overcome. I ask you to be patient until we can finally provide you with all the advantages and benefits. Hopefully the systems will run smoothly soon.

The preparations for our 50th birthday in Vienna at our World Congress in early September are in full swing. We have the commitment of over 380 top-class speakers and have put together an extremely exciting program for you. Within the next few days, we will send out the finished program and put it online. Our social media channels are already in high gear with the information and the registration numbers are encouraging.

We have the corona problem to deal with, especially as we are running courses all over the world. I am even more pleased that only a few courses have been postponed and hardly any participants cancel. At the same time, we are seeing a significant increase in the number of participants in our monthly webinars. An interesting observation.

Maybe some of you know already that at the end of the year, our Executive Director, Catherine

PLASTIC SURGERY

Foss, will go into well-deserved retirement after more than 20 years of service to ISAPS. We have started early with a succession search to fill this important position. I am pleased to inform you that at our Board meeting in New York in February we were able to interview the final candidates, all of whom are highly qualified and have a great deal of experience. We will shortly have a decision to communicate. Stay tuned!

Furthermore, after the board meeting, we added a leadership training course, which was the second module of two three-day courses that started last year in Vienna. Over 40 aspiring members of the National Secretaries group and Global Alliance Presidents attended to improve their leadership skills. The feedback was great and everybody learned a lot.

I would like to thank my entire Board and the many interested aspiring colleagues for their enthusiasm and commitment. We must not forget that all Board members, National Secretaries and Committee members work on a voluntary unpaid basis and in addition spend their time away from their families and well-attended practices.

Enjoy reading.

Dirk F. Richter, MD
President

ASSI® *Epstein Breast Retractors*

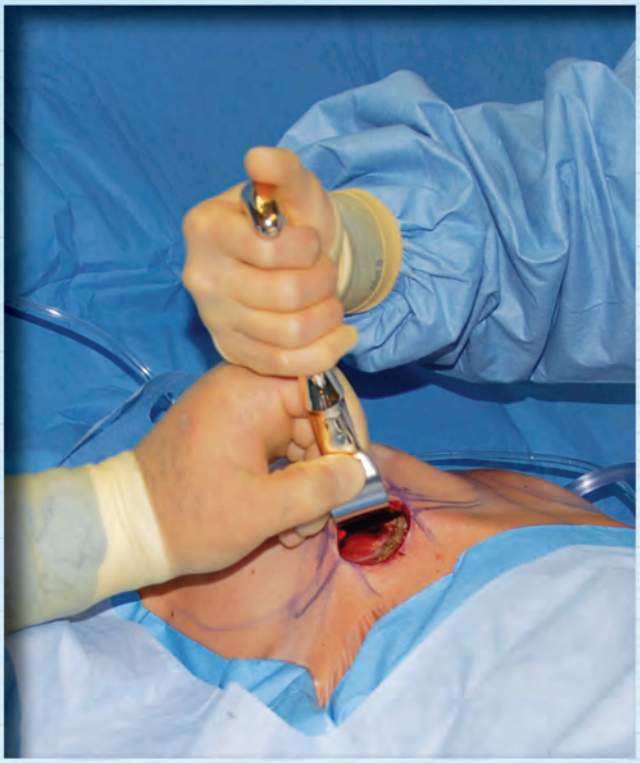

Epstein Breast Retractors: developed to create a retractor that provides unparalleled exposure and simultaneously reduce the strain on the surgeon's shoulder while permitting an atraumatic dissection, resulting in less pain and bleeding.

By reversing the handle we have achieved a "power assist" by the assistant. The minimum blade length outside the wound reduces the leverage on the surgeons shoulder.

The teeth surrounding the working end of the retractor ensures a gentle, yet firm hold on the tissue. The spatulated-end enables the surgeon to obtain maximal exposure at the point of surgical dissection.

ASSI®•ABR29426
Epstein Breast Retractor
90x27mm blade, w/36mm
spatulated working end with teeth

ASSI®•ABR29626
Epstein Breast Retractor
110x27mm blade, w/36mm
spatulated working end with teeth

ASSI®•ABR29726
Epstein Breast Retractor
140x27mm blade, w/36mm
spatulated working end with teeth

ASSI®•ABR29826
Epstein Breast Retractor
160x27mm blade, w/36mm
spatulated working end with teeth

ASSI®•ABR29926
Epstein Breast Retractor Set,
consisting of one each:
ASSI®•ABR29426, ASSI®•ABR29626,
ASSI®•ABR29726, ASSI®•ABR29826

Also available with fiber optic, suction
and fiber optic/suction, please inquire

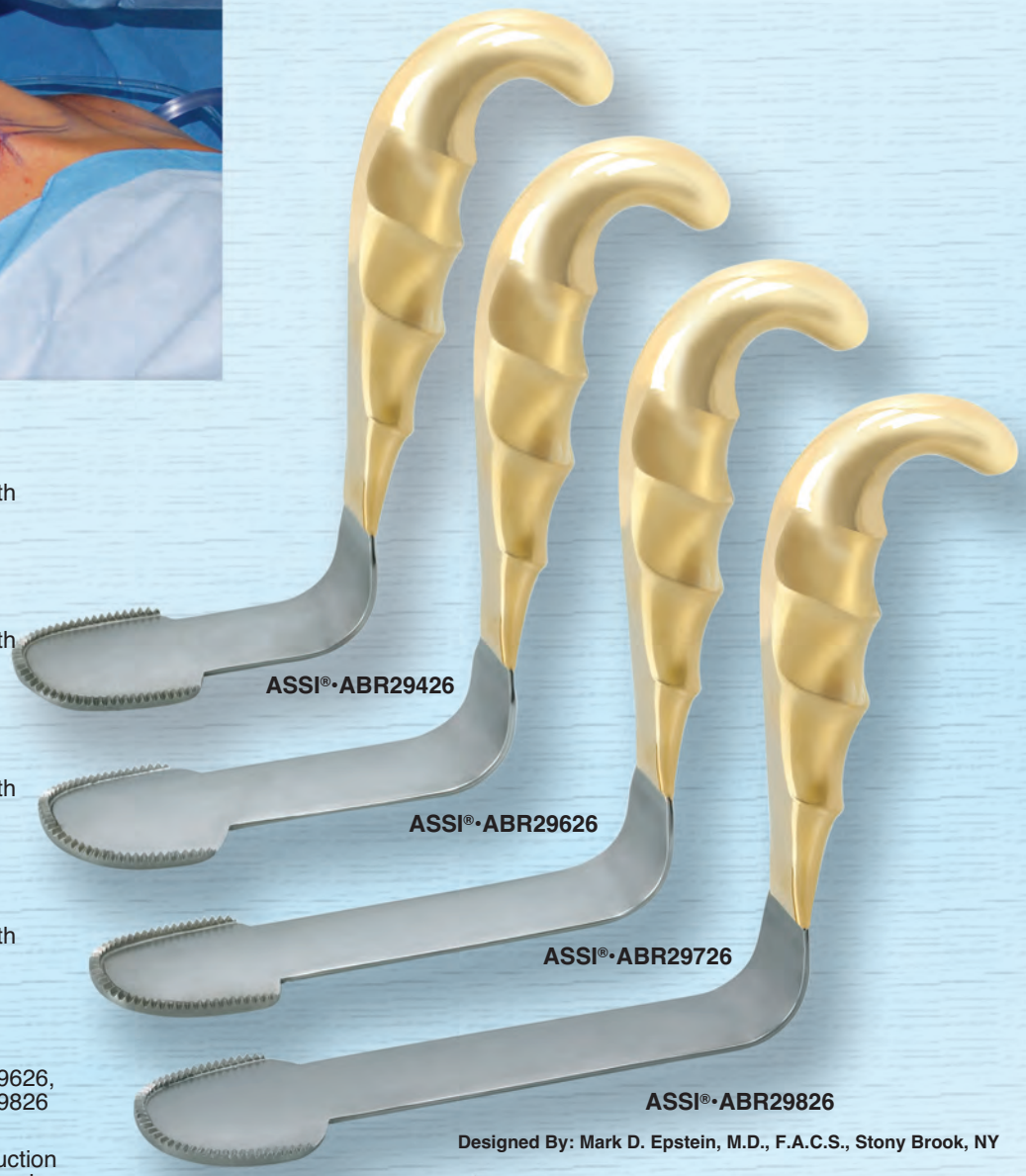

Designed By: Mark D. Epstein, M.D., F.A.C.S., Stony Brook, NY

assi®
ACCURATE SURGICAL & SCIENTIFIC INSTRUMENTS®
For diamond perfect performance®
accurate surgical & scientific instruments corporation
300 Shames Drive, Westbury, NY 11590
800.645.3569 **516.333.2570** fax: **516.997.4948** west coast: **800.255.9378** **www.accuratesurgical.com**

©2009 ASSI®

ISAPS GLOBAL ALLIANCE PARTICIPATING SOCIETIES

1. **ALGERIA**
   Algerian College of Plastic and Aesthetic Surgery (CACPRE)
2. **ARGENTINA**
   Sociedad Argentina de Cirugia Plastica Estetica y Reparadora (SACPER)
3. **AUSTRALIA**
   Australasian Society of Aesthetic Plastic Surgeons (ASAPS)
4. **AUSTRIA**
   Österreichische Gesellschaft für Plastische, Ästhetische und Rekonstruktive Chirurgie (ÖGPÄRC)
5. **AZERBAIJAN**
   Society of Plastic Surgery Azerbaijan (SPSA)
6. **BANGLADESH**
   Bangladesh Society of Aesthetic Plastic Surgeons (BSAPS)
7. **BELGIUM**
   Royal Belgian Society for Plastic Surgery (RBSPS)
8. **BOLIVIA**
   Sociedad Boliviana de Cirugia Plastica Estetica y Reparadora (SBCPER)
9. **BRAZIL**
   Sociedade Brasileira de Cirurgia Plástica (SBCP)
10. **BULGARIA**
    Bulgarian Association of Plastic, Reconstructive and Aesthetic Surgery (BULAPRAS)
11. **CANADA**
    Canadian Society for Aesthetic Plastic Surgery (CSAPS)
12. **CHILE**
    Sociedad Chilena de Cirugía Plástica, Reconstructiva y Estética (SCCPRE)
13. **CHINA**
    Chinese Society of Plastic Surgery (CSPS)
14. **COLOMBIA**
    Sociedad Colombiana de Cirugía Plástica, Estética y Reconstructiva (SCCP)
15. **CYPRUS**
    Cyprus Society of Plastic, Reconstructive and Aesthetic Surgery (CySPRAS)
16. **CZECH REPUBLIC**
    Czech Society of Aesthetic Surgery (CSAS)
17. **CZECH REPUBLIC**
    Czech Society of Plastic Surgery (CSPS)
18. **DENMARK**
    Dansk Selskab for Kosmetisk Plastikkirurgi (DSKP)
19. **DOMINICAN REPUBLIC**
    Sociedad Dominicana de Cirugía Plastica Reconstructiva y Estética (SODOCIPRE)
20. **EASAPS**
    European Association of Societies of Aesthetic Plastic Surgery (EASAPS)
21. **ECUADOR**
    Sociedad Ecuadoriana de Cirugía Plástica, Reconstructiva y Estética (SECPRE)
22. **EGYPT**
    Egyptian Society of Plastic and Reconstructive Surgeons (ESPRS)
23. **ESAPS**
    European Society of Aesthetic Plastic Surgery (ESAPS)
24. **ESPRAS**
    European Society of Plastic, Reconstructive and Aesthetic Surgery (ESPRAS)
25. **FINLAND**
    Suomen Esteettiset Plastiikkakirurgit r.y. (SEP)
26. **FRANCE**
    Société Française des Chirurgiens Esthétiques Plasticiens (SOFCEP)
27. **GEORGIA**
    Georgian Society of Plastic Reconstructive and Aesthetic Surgery (GEOPRAS)
28. **GERMANY**
    Deutsche Gesellschaft der Plastische, Rekonstruktive und Aesthetische Chirurgie, e.V. (DGPRÄC)
29. **GERMANY**
    Vereinigung der Deutschen Aesthetisch Plastischen Chirurgen (VDAPC)
30. **GREECE**
    Hellenic Society of Plastic, Reconstructive and Aesthetic Surgery (HESPRAS)
31. **GUATEMALA**
    Asociación Guatemalteca de Cirugía Plástica Estética y Reconstructiva (AGCPER)
32. **HUNGARY**
    Hungarian Society for Plastic, Reconstructive and Aesthetic Surgery (HSPRAS)
33. **INDIA**
    Indian Association of Aesthetic Plastic Surgeons (IAAPS)
34. **INDONESIA**
    Indonesian Association of Plastic Reconstructive and Aesthetic Surgeons (InaPRAS)
35. **IRAN**
    Iranian Society of Plastic and Aesthetic Surgeons (ISPAS)
36. **IRELAND**
    Irish Association of Plastic Surgeons (IAPS)
37. **ISAPS**
    International Society of Aesthetic Plastic Surgery (ISAPS)
38. **ITALY**
    Associazione Italiana di Chirurgia Plastica Estetica (AICPE)
39. **ITALY**
    Società Italiana di Chirurgia Plastica Ricostruttiva ed Estetica (SICPRE)
40. **JAPAN**
    Japan Society of Aesthetic Plastic Surgery (JSAPS)
41. **JORDAN**
    Jordanian Society for Plastic and Reconstructive Surgeons (JSPRS)
42. **KAZAKHSTAN**
    Kazakhstan Society of Aesthetic and Plastic Surgery (NSAPS)
43. **KOREA**
    Korean Society of Aesthetic Plastic Surgery (KSAPS)
44. **KUWAIT**
    Kuwait Society of Plastic Surgeons (KSPS)
45. **LEBANON**
    Lebanese Society of Plastic, Reconstructive, and Aesthetic Surgery (LSPRAS)
46. **MALAYSIA**
    Malaysian Association of Plastic, Aesthetic and Craniomaxillofacial Surgeons (MAPACS)
47. **MEXICO**
    Asociación Mexicana de Cirugía Plástica Estética y Reconstructiva (AMCPER)
48. **MOROCCO**
    Société Marocaine des Chirurgiens Esthétiques Plasticiens (SOMCEP)
49. **NETHERLANDS**
    Nederlandse Vereniging voor Esthetische Plastische Chirurgie (NVEPC)
50. **NICARAGUA**
    Asociación Nicaragüense de Cirugía Plastica (ANCP)
51. **NORWAY**
    Norwegian Society of Aesthetic Plastic Surgery (NSAP)
52. **OMAN**
    Omani Society of Plastic, Reconstructive and Aesthetic Surgery (OSPRAS)
53. **OSAPS**
    Oriental Society of Aesthetic Plastic Surgery (OSAPS)
54. **PAKISTAN**
    Pakistan Association of Plastic Surgeons (PAPS)
55. **PANAMA**
    Asociacion Panameña de Cirugia Plastica, Estetica y Reconstructiva (APCPER)
56. **PERU**
    Sociedad Peruana de Cirugía Plástica (SPCP)
57. **PHILIPPINES**
    Philippine Association of Plastic, Reconstructive and Aesthetic Surgeons (PAPRAS)
58. **POLAND**
    Polish Society of Plastic, Reconstructive and Aesthetic Surgery (PSPRAS)
59. **PORTUGAL**
    Sociedade Portuguesa de Cirurgia Plástica Reconstrutiva e Estética (SPCPRE)
60. **ROMANIA**
    Romanian Aesthetic Surgery Society (RASS)
61. **RUSSIA**
    Northeastern Society of Plastic and Reconstructive Surgeons (NESPRS)
62. **RUSSIA**
    Russian Society of Plastic, Reconstructive and Aesthetic Surgery (RSPRAS)
63. **SAUDI ARABIA**
    Saudi Plastic Surgery Care Society (SPSCS)
64. **SERBIA**
    Serbian Society of Aesthetic Plastic Surgeons (SRBSAPS)
65. **SERBIA**
    Serbian Society of Plastic, Reconstructive, and Aesthetic Surgery (SRBPRAS)
66. **SINGAPORE**
    Singapore Association of Plastic Surgeons (SAPS)
67. **SOUTH AFRICA**
    Association of Plastic, Reconstructive and Aesthetic Surgeons of Southern Africa (APRASSA)
68. **SPAIN**
    Asociación Española de Cirugía Estética Plástica (AECEP)
69. **SPAIN**
    Sociedad Española de Cirugía Plástica Reparadora y Estética (SECPRE)
70. **SWEDEN**
    Svensk Förening för Estetisk Plastikkirurgi (SFEP)
71. **SWITZERLAND**
    Schweizerische Gesellschaft für Aesthetische Chirurgie (SGAC)
72. **SWITZERLAND**
    Swiss Society of Plastic, Reconstructive and Aesthetic Surgery (SSPRAS)
73. **TAIWAN**
    Taiwan Society of Aesthetic Plastic Surgery (TSAPS)
74. **TAIWAN**
    Taiwan Society of Plastic Surgery (TSPS)
75. **THAILAND**
    Society of Aesthetic Plastic Surgeons of Thailand (THSAPS)
76. **TURKEY**
    Turkish Society of Aesthetic Plastic Surgery (TSAPS)
77. **UKRAINE**
    Ukrainian Association of Plastic, Reconstructive and Aesthetic Surgeons (UAPRAS)
78. **UKRAINE**
    Ukrainian Society of Aesthetic Plastic Surgeons (USAPS)
79. **UNITED ARAB EMIRATES**
    Emirates Plastic Surgery Society (EPSS)
80. **UNITED KINGDOM**
    British Association of Aesthetic Plastic Surgeons (BAAPS)
81. **UNITED KINGDOM**
    United Kingdom Association of Aesthetic Plastic Surgeons (UKAAPS)
82. **UNITED STATES**
    American Society for Aesthetic Plastic Surgery, Inc. (ASAPS)
83. **VENEZUELA**
    Sociedad Venezolana de Cirugía Plástica, Reconstructiva, Estética y Maxilofacial (SVCPREM)
84. **VIETNAM**
    Vietnamese Society of Aesthetic and Plastic Surgery (VSAPS)

GLOBAL ALLIANCE

ALGERIA

MUSTAPHA AÏT AÏSSA, MD - ALGERIA
President, Algerian College of Plastic and Aesthetic Surgery

Founded in 2015, the **Algerian College of Plastic and Aesthetic Surgery (CACPRE)** represents all board-certified surgeons in Algeria having the vocation to be specialized in the field of plastic and cosmetic surgery.

The mission of CACPRE is to advance quality care to plastic surgery patients by encouraging high standards of training, ethics, physician practice and research in plastic surgery. To support its members in the provision of excellent patient care, CACPRE provides education, advocacy, practice support and enhanced public awareness of the value of plastic surgery, while fostering the highest professional, ethical, and quality standards. The society is a strong advocate for patient safety and requires its members to operate in accredited surgical facilities that have passed rigorous external review of equipment and staffing.

The CACPRE website www.cacpre.org welcomes visitors, professionals and those interested in learning about plastic surgery procedures and finding a highly-trained, qualified plastic surgeon.

Search engines and social media networking are becoming valuable tools to gather information about the specialty. Our website offers a resource for trusted information about cosmetic and reconstructive procedures, how to choose a qualified plastic surgeon, and plenty of useful content about the benefits and risks of specific procedures, a before-and-after photo gallery and video content featuring real patients who share their experiences.

The Algerian Ministry of Higher Education in the field of surgery certifies every member. Those who have the vocation to be subspecialized in plastic surgery have undergone many years of training and passed rigorous examination and are dedicated to the continuing medical learning for the global safety of our patients.

Every surgery carries some degree of risk. Plastic surgeons who are members of CACPRE work in licensed/accredited facilities ensuring that our surgeons will have the necessary assistance and equipment to protect you during surgery. Through their combination of training, ethics and accreditation requirements, members offer the safest environment in which to undergo a plastic surgical procedure. Plastic surgery is like a trip. If you prepared for it properly, you will surely return satisfied.

Since the beginning of this discipline, history continues to provide more innovation and care for those suffering disfigurement or physical anomalies, including breast reconstruction, pediatric craniofacial anomalies, cosmetic concerns, face and hand transplant, migraine surgery, regenerative medicine, hand surgery – and much more. Sharing knowledge with colleagues in order to give the best and the safest care to our patients is what matters.

EDUCATION COUNCIL UPDATE

VAKIS KONTOES, MD, PHD – GREECE
Chairman, ISAPS Education Council

My best wishes to all ISAPS members and their families for a Happy New Year in 2020, full of health, joy, professional and personal success.

The organization of our World Congress in Vienna in September 2020 is progressing at full speed and we are looking forward to the celebration of the 50th anniversary of our society. The program is ready and has been uploaded to our website. Some minor changes might be made in special cases, but registration on our web site and free papers submission are now open. There is a lot more to be done, but the Education Council together with the Board, our President and the marketing office and Congress organizers are fully dedicated to completing all necessary tasks so that everything will be ready for this top event of our Society.

Before I move on to a brief description of the Education Council events that took place in recent months, I would like to remind you about two issues related to the organization of ISAPS educational events worldwide, very useful for the local organizers of such events.

One is about our Global Sponsor Program for industry that supports our vision financially. Among the benefits to which they are entitled, our Global Sponsors can request a free exhibit booth at a certain number of educational events. The Executive Office must request the space from the local organizer on behalf of the Sponsor and I would appreciate their kind cooperation very much, in view of honoring our commitments to our Global Sponsors. Here, I have to point out that no direct negotiation between the local organizers and the Sponsor is permitted, as it would only create difficulties and organizational problems. The Sponsors must first contact the Executive Office prior to any discussion with the local organizers who, if contacted directly, must refer the Sponsor to the Office.

The other issue is waiving registration fees for members at certain membership levels to attend Courses or Symposia worldwide. Again, the Executive Office will inform the local organizers regarding the procedure and settlement as ISAPS is obliged to pay the fees for these members. Our new membership structure, which has been enthusiastically received by our members, provides this type of benefit for certain levels and I would appreciate your cooperation in this matter.

In the months of September, October, November and December 2019, the Education Council was happy to support and organize three courses, seven Symposia and endorse thirteen meetings worldwide.

In November, we had the opportunity to organize live surgery Course in Monaco with very high class international faculty; a very successful Course in Riyadh, Saudi Arabia; and in January, the landmark ISAPS Aesthetic Dissection Course at the University of Liege in Belgium which has become very popular for its high standard training in rhinoplasty and facial aesthetic procedures. The Symposia that were organized took place in Brazil, Colombia, Australia, Poland, Canada and the UK. Two webinars were also organized and broadcast worldwide from Monaco and Italy, in addition to monthly webinars, organized by ISAPS.

The 3rd Module of the F.A.S.T. Program on Body Aesthetic Surgery was held very successfully in Moscow in November, followed by a glamorous award ceremony where the participants who attended all three Modules, and were successful in the three multiple choice question tests, were awarded their official diploma of training and became eligible for the benefits that ISAPS is offering to them through this training program. We are very happy, following this amazing success, to approve a new F.A.S.T. Program in Russia for 2020.

On January 23rd, 2020, the first ever official ISAPS Symposium in the United States in cooperation with the Southeastern Society of Plastic and Reconstructive Surgeons (SESPRS) took place in Atlanta, Georgia with great success. The Education Council would like to thank all colleagues involved for this successful outcome and is looking forward to more in the future.

Continued on page 10

On February 15-19, 2020, an ISAPS Symposium took place in India together with the Indian Association of Aesthetic Plastic Surgery (IAAPS, AeSURG) during a cruise where the annual meeting of this Society was scheduled. On March 12-14, the first ever ISAPS Course on Aesthetic Surgery of Face and Body was held in Dhaka, Bangladesh.

All these meetings and related information can be found on the Calendar of events on our website, https://www.isaps.org/events/ which apart from the upcoming programs, also stores previous events.

I remind readers that explanations of the various educational options supported by ISAPS can be found on our website at https://www.isaps.org/medical-professionals/education-council/ Here you can download Education Council Guidelines, F.A.S.T. Guidelines and an application, and the application for Endorsed Programs. Education Council members are also listed there so you can contact any of them for more information. Before initiating a Course or Symposium, members are asked to contact me, as Education Council Chair, at vakiskont@gmail.com to confirm your preferred dates in order to avoid conflicts with other meetings, and to understand the procedure.

Our sincere thanks to all of you for supporting our ISAPS Education Mission from any position in the ISAPS family. We urge you to keep in close contact with us for any matter regarding educational issues in aesthetic surgery. We will be very happy to support and help your initiatives.

ISAPS MEMBERS WRITE

Wine has long been associated with health and longevity, and wine chemistry has played a central role in understanding the science of anti-aging. Yet new global studies implied a different paradigm, with headlines proclaiming "No amount of alcohol is safe." Though such conclusions were overstated, the epidemiological evidence was troubling for researchers and wine lovers alike. In Wine & Health, the first wide-ranging analysis of the existing science on the topic, author Richard A. Baxter, MD argues that the answers emerge as a set of new paradoxes: Studies may be globally accurate while at the same time missing wine's position in health and well-being; it remains true that on average, wine drinkers outlive nondrinkers and maintain mental sharpness in old age; and evidence of wine's benefits can be found in the very studies telling us of alcohol's risk to public health. Dr. Baxter explains in objective terms that though modern science has complicated our relationship to alcohol, wine's value in human flourishing remains undiminished.



COURSE REPORT

ISAPS COURSE SAUDI ARABIA AND 2ND INTERNATIONAL SAUDI PLASTIC SURGERY CONGRESS: *AN EVENT TO REMEMBER*

JAMAL JOMAH, FRCSC, FRCSED, ABHRS, FACS – SAUDI ARABIA
President of Saudi Plastic Surgery Care Society

FUAD HASHEM, MD, MBBS, FRCSC – SAUDI ARABIA
ISAPS National Secretary for Saudi Arabia

On December 6-8, 2019, the well-attended congress organized by Saudi Plastic Surgery Care Society (SPSCS) headed by Dr. Jamal Jomah, President, Dr. Fuad Hashem, Vice President and ISAPS National Secretary for Saudi Arabia together with the SPSCS Board Members, was graced by none other than the ISAPS President, Dr. Dirk Richter, and President-Elect, Dr. Nazim Cerkes.

FEATURE / HIGHLIGHTS

This congress was unique being a 5-in-1 event as we had five entities collaborating to create one event sharing one theme in patient care and those entities are:

1. ISAPS Course Saudi Arabia – International Society for Aesthetic Plastic Surgery (ISAPS)
2. International Nursing Symposium – King Saud University – College of Nursing
3. Riyadh Breast Meeting – King Faisal Specialist Hospital & Research Centre Gen. Org.
4. Residents Research Day – Saudi Commission for Health Specialties (SCFHS)
5. Craniofacial Anomalies & Cleft Symposium – King Saud Bin Abdulaziz University for Health Sciences & Saudi Craniofacial Anomalies and Cleft Society

Continued on page 12

This congress is another building block in the goals set by our government in achieving the Vision of 2030.

The main scientific highlights were

1. The various tracks that involved the specialty of Plastic Surgery mainly Nursing, Craniofacial and Oncoplastic Surgeons.
2. The diversity of the presentations and number of talks were:

Live Surgery (Webinar)	4
Workshops	9
Residents Research	20
Posters	36
Speakers	145
Lectures	160

Live surgery transmission webinar

Facelift	Dr. Gerald O'Daniel
Cleft Lip Rhinoplasty	Dr. Nazim Cerkes
Tumor Resection	Dr. Shawna Willey
Breast Reconstruction	Dr. Fuad Hashem

SPEAKERS

The congress encompassed speakers and participants from thirty-one countries, who shared their knowledge and expertise with us.

EVENT MANAGEMENT SYSTEM

We utilized the most up-to-date software application in congress management namely WHOVA that was downloaded by most of the attendees.

AWARDS/RECOGNITION

Prof. Mohamed Al Qattan was given distinguished recognition for his invaluable contribution in the field of Plastic Surgery. Having all his qualifications, achievements and contributions, he truly deserved recognition. In return, Prof. Mohamed Al Qattan personally selected the best articles published this year. The winners were given *Prof. Al Qattan Meritorius Awards*.

PROF. AL QATTAN MERITORIUS AWARDS

1st – Dr. Jamal Jomah
Article: Nasal Skin Thickness Measurements Using Computed Tomography in an Adult Saudi Population
Journal: Plastic and Reconstructive Surgery - PRS Global Open

2nd – Dr. Taghreed Al Humsi
Article: Low-Cost Desktop-Based Three-Dimensional-Printed Patient-Specific Craniofacial Models in Surgical Counseling, Consent Taking, and Education of Parent of Craniosynostosis
Journal: Journal of Craniofacial Surgery

3rd – Dr. Salah Aldekhayel
Article: The Use of Venous Coupler in Pediatric Free Tissue Transfer: Case Series and Literature Review
Journal: Plastic and Reconstructive Surgery – PRS Global Open

BEST POSTER

Qutaiba Shah Mardan – Angioleiomyoma of the Proper Ulnar Digital Artery: Care Report - received an iPhone 11 courtesy of our strategic partner Rose Aljazera, and a certificate.

RESIDENTS' RESEARCH

The first-place winner was awarded a sponsored attendance to ISAPS 2020 in Vienna, Austria (tickets, accommodation plus 500 USD allowance), and a certificate.

1st - Ahmed Alharbi
Research Title: Does skin thickness affect satisfaction post rhinoplasty?

2nd - Nehal Mahabat
Research Title: Intensive Care Unit Monitoring post pharyngeal flap: retrospective study in KFSH& RC

3rd - Alwaleed Alammar
Research Title: Novel pre-mastectomy permanent implant reconstruction (PPIR): initial experiences from Saudi Arabia.

BEST PHOTO

Dr. Abdulaziz AlDayel – Maxillary Obturator with 179 likes - received an iPhone 11 courtesy of our strategic partner Rose Aljazera

PRESIDENT'S LUNCH MEETING

We were fortunate to have the ISAPS President and President-Elect at a lunch meeting. Dr. Richter expressed his support to the Arab Society Presidents (UAE, Iraq, Kuwait, Jordan, Lebanon, Egypt, Algeria and Oman). Furthermore, he promised to support the local societies for any activities.

L-R: Dr. Jamal Jomah, Dr. Fuad Hashem, while giving the plaque of appreciation to the ISAPS President, Dr. Dirk Richter.

The Saudi Plastic Surgery Care Society Board Members, ISAPS Organizers with Dr. Dirk Richter.

President's Lunch Meeting with the Board Members and Arab Society Presidents. L-R: Dr. Dirk Richter, Dr. Nazim Cerkes, Dr. Zuhair Al Fardan (UAE), Dr. Fuad Hashem, Dr. Jamal Jomah, Dr. Mohamed Amir Mrad.

Group photo with the speakers.

Dr. Dirk Richter presenting his Keynote Speech.

ISAPS Course – speakers, guests, and attendees.

COURSE REPORT

ISAPS AESTHETIC SURGERY DISSECTION COURSE 2020

JEAN LUC NIZET, MD – BELGIUM
Course Director

IVAR VAN HEIJNINGEN, MD – BELGIUM
Course Director

The 2020 dissection course in Liège, Belgium was another great success. It was already fully booked by December 2019.

On January 21 to 23, the sixth ISAPS Fresh Cadaver Aesthetic Surgery Dissection Course in Liège, Belgium took place. There were thirty-three particpants of whom twenty-eight were practicing plastic surgeons and five were residents. They came from four continents: Asia, South America, USA and most from Europe obviously. Ten of them were already ISAPS members. Twenty-nine came for the Nose and Face course, four for the face course only.

The set-up of the course was slightly different compared with previous years and more focused on teaching actual procedures. It turned out to be a good move. The first day on Rhinoplasty taught the attendants how to do an open rhinoplasty procedure. The course instructors with a particular interest in this were: Pascal Castus, Bahram Dezfoulian, Olivier Gerbault and Serge De Fontaine who had prepared a very precise roadmap for the attendees to follow. Course instructor Peter Palhazi gave excellent presentations on anatomy, specifically focusing on the pitfalls of the procedures taught.

'Very useful course full of theoretical and especially practical details…"

ISAPS President-Elect, Nazim Cerkes, closed the day with a "live" demonstration and video presentation of what the attendees needed to know. They went to rest after that and the faculty shared an excellent meal during the faculty diner which is an important part of the Liège tradition.

Over the next two days, we focused on facial procedures. Faculty members Carlos Parreira and Daniel Labbé (who came despite the French railroad strikes) supported us and each presented interesting additions to the course prepared by the course instructors already mentioned plus Vakis Kontoes, Alex Verpaele, Gianluca Campiglio, Jan Fabré and the two course directors.

On Friday, we focused on local anesthesia, non-surgical procedures, temporal lift, direct browlift and eyelid procedures: upper blepharoplasty, single suture traction technique, transconjunctival and direct lower blepharoplasties. We closed

the day with a presentation on peri-orbital rejuvenation by Carlos Parreira. Friday evening a complimentary dinner was organized where the attendees and faculty enjoyed great food and company. The relaxed atmosphere helped everyone get acquainted with each other and spend a nice evening together.

The next day, we continued with a presentation by Daniel Labbé on the fixation points of head and neck before we focused on facelift techniques starting with MACS, then the SMAS procedures. The afternoon was for neck procedures, midline platysmaplasty, lateral fixation and platysma transection and ending with lipoplasty and answering questions.

'Impressive faculty, keep the ratio instructors/trainees this high, perfect course...."

The participants rated the overall value 4.9 on a scale of 5, especially the cadaver lab. The facilities and the quality and usefulness of course communications, registration and website were also rated very high. They appreciated the quality of the cadavers with ratings of 4.7 out of 5 and the conference logistics, food and refreshments with 4.7 out of 5.

"Thank you so much, the best course ever!"

The Faculty and Course Instructors were rated "very good" with an average score of 4.7 out of 5 with a narrow margin from 4.5 to 5.0 so all scored as was expected and wished for. From the Course Instructors' side, everyone spontaneously offered to come back because they had a good time and enjoyed contributing to this course.

To all the ISAPS faculty, and each one individually, the organizers wish to express their gratitude for the excellent performance.

The next course is planned January 21-23, 2021. We look forward to next year.

ISAPS VISITING PROFESSOR PROGRAM

UKRAINE 2020

OLEG TKACH, MD – UKRAINE
ISAPS National Secretary for Ukraine

On February 7-8, another ISAPS Visiting Program Program (VPP) took place in Kiev, the beautiful capital of Ukraine on the banks of the Dnepr river. This event was promoted by ISAPS and organized by me, as ISAPS National Secretary for Ukraine, with the local support of the Ukrainian Association of Plastic, Reconstructive and Aesthetic Surgeons (UAPRAS). Gianluca Campiglio, MD, PhD, from Milan (Italy), 2nd Vice President of ISAPS was our Visiting Professor. He shared his 30 years' experience in aesthetic surgery with the Ukrainian plastic surgeons during two very intensive days of lectures and live surgeries. The VPP was held in one of the most exclusive and charming international hotels in the city, just in front of Santa Sophie Cathedral. The event was attended by over 75 plastic surgeons of different ages and experience, including ISAPS members, young surgeons and doctors in training.

The VPP was opened by the president of UAPRAS, Andrey Kharkov, who welcomed the participants and conveyed the greetings of the national society, one of the 84 members of the ISAPS Global Alliance. Soon after, I made a short presentation representing ISAPS and listing all the benefits of membership. I also invited the few non-members in the room to apply during the meeting.

The scientific program of the VPP was dedicated to the discussion of the most important problems and prospects

Figure 1 – Dr. Kharkov (UAPRAS President), Dr. Pinchuk (Director of Certus Clinic), Dr. Campiglio (ISAPS Visiting Professor and ISAPS 2nd Vice President), and Dr. Tkach (ISAPS National Secretary for Ukraine).

Figure 2 – Dr. Campiglio during one of the talks on the first day.

for the development of modern plastic surgery, deepening our understanding of the most performed procedures for any anatomical area. A rich program of more than 20 different lectures, each one lasting 15 minutes and enriched of surgical videos, was presented during these two days. Friday morning was dedicated to face and neck lift, blepharoplasty, rhinoplasty and otoplasty presentations while Saturday morning was focused on breast surgeries (augmentation, lift and reduction) and body contouring. Dr. Campiglio also conducted two long live surgeries from Certus Clinic that were broadcast to the auditorium, thus giving the possibility to the audience to ask questions and request clarification during every step of the procedures. On Friday, a full-face lift with SMAS flap, including upper and lower blepharoplasty with browpexy and canthopexy, was performed. Dr. Campiglio also showed the use of the hemostatic net at the end of the operation. On Saturday afternoon, a mastopexy with auto-augmentation was performed on a patient with ptotic breast who declined the implantation of prostheses.

Special thanks go also to local distributors of top-level companies such as Polytech, Mentor, Motiva, Univet and Eurosilicone that contributed to support the event financially. At the end of two very intensive days this ISAPS educational initiative was greatly appreciated by the participants, as witnessed by the very positive feedback that I received during the event and in the following days. It has certainly contributed to reinforce ISAPS as the strongest point of reference for training in aesthetic plastic surgery in Ukraine, nowadays and in the future.

Figure 4 – Dr. Tkach, Dr. Campiglio, and Dr. Savinchev (anesthesiologist) at the end of the second live surgery.

Figure 3 – Broadcasting of live surgeries from the Certus Clinic to the auditorium.

ISAPS VISITING PROFESSOR PROGRAM

UNITED STATES

NAZIM CERKES, MD, PHD – TURKEY
ISAPS President-Elect

I was honored to be the ISAPS Visiting Professor at the University of Utah in Salt Lake City on February 25-26, 2020. There I spent much time with residents, fellows and faculty at the Division of Plastic Surgery chaired by Dr. Jay Agarwald.

On February 25, they hosted a very nice dinner at a local restaurant and I was introduced to 11 faculty, 14 residents, 2 fellows and many community plastic surgeons of the division that participate in teaching at that institution.

The next morning, I gave Grand Rounds to the entire Division of Plastic Surgery followed by several lectures on Rhinoplasty. Then the residents presented cases for my analysis and recommendations. That was followed by a very active and dynamic educational session.

In the afternoon, we had a fresh cadaver dissection on all aspects of rhinoplasty. I demonstrated the current techniques of open rhinoplasty and the residents dissected and learned quite a lot.

They were very happy with my visit which helped to expose ISAPS to plastic surgery colleagues in Utah.

I wish to thank Dr. Cori Agarwald and her entire faculty for their warm welcome and for opening the doors to ISAPS educational activities.

FEATURE

BREAST IMPLANT-RELATED SYMPTOMS

Women with implanted silicone breast implants (saline and silicone gel) as early as 1980 reported a variety of vague symptoms that were without a medical explanation. Unproven theories of breast implant-caused disease were ultimately disproven. Little is known about the long-term health history of these women with alleged systemic symptoms who received compensation from the Dow Corning Breast Implant litigation of the 1990's.

In 2011, the term *autoimmune/inflammatory syndrome induced by adjuvants* (ASIA) was proposed to refer to symptoms linked to previous exposure to adjuvants, one of which is silicone. Symptoms of ASIA can include nonspecific signs and symptoms such as muscle pain, joint pain, fatigue, neurological symptoms, and cognitive impairment, or the development of an autoimmune disease, such as fibromyalgia. Data obtained from these studies generally have significant limitations, such as small sample sizes and lack of a control group. Some patients with ASIA have reported improvement in systemic signs and symptoms following explantation of silicone breast implants while others have not. Systemic symptoms reported as ASIA appear identical to what is now termed "breast implant illness."

Theories of autoimmune causation from breast implants have surfaced, but have been largely disproved in studies published in the *New England Journal of Medicine*, Institute of Medicine, and *Annals of Internal Medicine*. The likelihood of a woman with a personal or family history of autoimmune disease who receives breast implants developing health problems has never been established.

The US FDA, Health Canada, and Australian Therapeutic Goods Administration have concluded, "There is no evidence of increased risk of connective tissue diseases with breast implants."

> "To the best of our body of scientific knowledge to date, there have not been any concrete or evidence-based studies or peer-reviewed data concerning the formation of a new syndrome: silicone implant illness." Rod J. Rohrich, M.D., Plast. Reconstr. Surg. 144: 98, 2019.

BII CANNOT BE DIAGNOSED THROUGH CURRENT SCIENTIFIC TESTING

There is no test to diagnose BII, nor an imaging study that proves its existence. It cannot be diagnosed by a patient comparing her symptoms to those listed on the internet as BII. BII-similar symptoms occur in women who have never had breast implants. Women with these unexplained symptoms develop strong opinions of causation, despite an absence of objective findings. They are desperate and vulnerable. The first step is to be seen by a plastic surgeon regarding the status of their breast implants. Next, referral to an appropriate specialist for diagnosis and treatment. Many of the symptoms that are attributed to BII are caused by specific diseases that are not related to breast implants.

Continued on page 20

ICD-10 DIAGNOSIS CODE FOR BII

BII advocacy/activist groups have petitioned the regulatory agencies (US) to develop a specific ICD-10 diagnosis code for Breast Implant Illness and to acknowledge its existence in device labeling. These groups believe that their members have an illness that has been caused by breast implants and that for them to obtain medical treatment, there is the need for a specific BII ICD-10 diagnosis code. They are seeking a political solution to create BII as a disease in the absence of scientific evidence. This will force physicians to become disability and disease arbiters. The status of this matter at this time is unknown.

Desperate patients who suffer from medically unexplained symptoms often seek help over the worldwide internet. The internet is not regulated and there are sites in every country where fake medical advice, unverified medical treatments, and unscrupulous physicians can be found. Patient harm and death has occurred when unproven medical therapy has been used in the case of stem cell clinics treating disease conditions. The granting of an ICD-10 diagnosis code for BII would only make matters worse for patients worldwide as it would facilitate the spread of misinformation about BII and unproven treatments. This would become a worldwide patient safety problem.

ICD-10 BREAST CODES ALREADY EXIST

The ICD-10 is quite robust with regards to a code for the presence of breast Implants (Z98.82), mechanical complication of breast implants (T85.49XA), and capsular contracture (T85.44). There is a huge potential for misdiagnosis, mistreatment, and harm if an ICD-10 diagnosis code is given to BII and the wrong treatment is given for a symptom.

According to peer-reviewed scientific literature and data, there is no compelling scientific evidence whatsoever to justify granting an ICD-10 diagnosis code for the medically unexplained symptom complex referred to as Breast Implant Illness. The various symptoms that have been attributed by advocacy/activist groups to BII already have ICD-10 diagnosis codes and patients can seek treatment through this pathway.

BII AND PLASTIC SURGEONS

It is important to consider the ramifications of this as it relates to patients. As compassionate plastic surgeons, we believe that it is important to focus on the mitigation of suffering despite mischaracterization of its underlying cause. Women with these symptoms deserve our respect, sympathy, and attention to understanding this issue. Plastic surgeons understand that women with unexplained symptoms want to feel better and need safe treatments.

Plastic surgeons worldwide and their organizations sincerely hope that someday research that is currently being performed can determine the precise cause of these medically unexplained symptom complexes such as BII and Fibromyalgia in order to mitigate patients' suffering and determine who may be at risk for their occurrence. Scientifically-proven treatment is needed to prevent patient harm.

ADVICE FOR BREAST IMPLANT PATIENTS

For women who have breast implants, the plastic surgeon remains the best source of information regarding the safety and long-term effectiveness of breast implants, not unscientific medical advice that is found on the worldwide internet. Patients require periodic follow up care to monitor their outcomes and general health. If patients elect to have their breast implants removed for personal reasons, this is an appropriate decision, just like it was to have them placed originally. It may not be possible or advisable to have a capsule that is densely adherent to the ribs totally removed, for risk of pneumothorax. In the case of BIA-ALCL, total capsulectomy is mandatory.

FEATURE

DO PLASTIC SURGEONS UNDERGO COSMETIC SURGERY? AN INTERNATIONAL COMPARISON

DARYA D. KAZEI, MD – UNITED STATES

SAMUEL J. LIN, MD, MBA – UNITED STATES

LAURE-ANNE VAN LOON, BSC – UNITED STATES

ISAPS recently circulated the survey entitled 'Do Plastic Surgeons Undergo Cosmetic Surgery?' by Beth Israel Deaconess Medical Center/Harvard Medical School which asked plastic surgeons if they had undergone cosmetic procedures. We would like to thank everyone who participated, and are very pleased to announce that we received a total of nearly 750 responses.

According to the International Society of Aesthetic Plastic Surgery's (ISAPS) latest report, the number of surgical and non-surgical cosmetic procedures has increased by respectively 24.5% and 15.0% in the last four years.[1] The impact of social media on the rising popularity of cosmetic surgery has been a topic of discussion in the media. Celebrities and popular influencers no longer only share details about their make-up routine, but also openly talk about the cosmetic procedures they have undergone – if not broadcasting them live. Does this rising popularity also reflect in the population of individuals who perform these cosmetic procedures?

To our knowledge, only two studies have focused on the attitude of plastic surgeons towards undergoing cosmetic procedures.[2,3] One study published in 2009, by Gurunluoglu et al, concluded that two-thirds of the responding plastic surgeons had undergone a non-surgical procedure, and one-third of respondents had undergone a surgical procedure, the most popular being botulinum toxin injections and liposuction. These findings were in line with the ISAPS reports which stated that botulinum toxin injection, breast augmentation or surgery for gynaecomastia, liposuction and blepharoplasty were the most performed procedures in 2018.[1]

The aforementioned study was limited by the inclusion of only American plastic surgeons. However, not all countries have a comparable relationship to cosmetic surgery. The United States accounts for the highest number of cosmetic procedures performed worldwide (15.1%), followed by Brazil (13.8%). What stands out is the total number of non-surgical procedures in the US is larger than for surgical procedures. Brazil accounts for a higher number of surgical procedures – for example, surgeons in Brazil perform more than double the number of otoplasties and buttock augmentations when compared to the US. In contrast, Portugal and Saudi Arabia rank last and second to last accounting for only 0.6% and 0.5% of the total cosmetic procedures respectively.[1]

Continued on page 25

UPDATE ON ISAPS GLOBAL ACCREDITATION PROGRAM

OZAN SOZER, MD – UNITED STATES
Vice Chair, ISAPS Education Council

Dear Members,

The Global Accreditation Committee is pleased to announce that a critical step forward has been taken in our project. Drs. Foad Nahai, Robert Singer, Renato Saltz and I met with the executives of the American Association for Accreditation of Ambulatory Surgery Facilities (AAAASF) at the Dallas/Fort Worth Hyatt Hotel in Texas on February 8th. The meeting was fruitful and AAAASF agreed to support our project. AAAASF is a renowned organization that credentials surgical facilities all over the world. They have the reputation and expertise that will complement our project.

Our next goal will be the training of ISAPS Surveyors. This is a complex process and the crucial first step is a four-hour, in person training course. The first such course will take place in Las Vegas, Nevada during the ASAPS meeting. It is scheduled from 8am to 1pm on April 24th at the Mandalay Bay Hotel. This training course is open to all ISAPS members at no cost. I believe this is a wonderful opportunity to learn all the safety issues of a surgical facility from world experts. We will have a similar training course during ISAPS World Congress in Vienna. We anticipate credentialing a few facilities in Vienna, right before and after the Vienna meeting.

A specific Congress session will include a Global Accreditation Panel where our members will hear the details of the project and can directly ask questions of the experts.

Anyone who is interested in credentialing surgical facilities should participate in one of these training courses and attend the Global Accreditation Panel session on Thursday, September 3rd during the Congress in Vienna.

We believe this is an important step for patient safety all over the world. Members who wish to become an official ISAPS Surveyor can email me at osozer@mac.com or Catherine Foss at isaps@isaps.org **To register for the training session during the ASAPS meeting on April 24**, email or fax the completed registration form to AAAASF. To Email, send to ldeubel@aaaasf.org or fax the form to 1-847-775-1985

I look forward to your participation in this great project.

PATIENT SAFETY

ABDOMINOPLASTY

JAMES FERNAU, MD – UNITED STATES
ISAPS Patient Safety Committee

Patient safety in abdominoplasty starts with a thorough history and screening for bleeding and clotting disorders. The physical exam should assess previous abdominal scars, rule out hernias, assess for diastasis rectus and hip asymmetries.

Absolute contraindications to abdominoplasty would include morbid obesity (BMI of 40 or greater), a severe bleeding diathesis and a significant history of deep venous thrombosis and/or pulmonary embolism. Some consider age greater than 65, diabetes mellitus, hypertension, cardiac conditions, large upper abdominal scars and excessive weight (BMI greater than 30) as contraindications.[1] One study showed abdominoplasty, with or without concurrent liposuction, in obese patient with an average BMI of 34.9, was safe and effective.[2] Abdominoplasty in the female patient is best suited after the family is complete and no further pregnancy is expected. Smoking is always a concern. Most recommendations include smoking cessation 4 weeks prior to surgery and 4 weeks after surgery. However, the rate of infections is still significant because the lifetime number of cigarettes smoked is associated with more infections.

A very important comorbidity that is commonly missed is obstructive sleep apnea (OSA). These patients should have a pulmonary consult and the surgery performed in a hospital setting with a possible overnight observation. Preoperatively, a high-protein low-carbohydrate diet is recommended so the patient can transition into this diet more comfortably in the post-operative period. The following supplements are helpful for protein synthesis: L-arginine, glutamine, vitamin C and zinc.

I recommend using Dr. Lorne Rosenfield's surgical checklist published in the ASAPS Scissors on the Seam Patient Safety Site.[3] A five-day decontamination protocol is instituted.[4] The ERAS protocol provides a safe, quick, and less painful recovery.[5] In the post-operative period, I encourage no narcotics, early ambulation, oral ibuprofen 600mg every six hours along with Tylenol 1000mg every six hours instead of narcotics.

Concerning prophylactic antibiotics, the current standard of practice is to give a dose of antibiotic such as cefazolin (Ancef) 40 to 60 minutes before incision and every four hours or longer for other antibiotics such as clindamycin. For venous thrombosis embolism prophylaxis, it is worth considering non-general anesthesia which would include monitored anesthesia care, local anesthesia with sedation or neuraxial (epidural) anesthesia. We strongly recommend intermittent pneumatic compression devices which are superior to elastic compression stockings. It is worth using the 2005 Caprini instrument for venous thromboembolism risk stratification.[6] Consider chemoprophylaxis on a case by case basis in patients with the Caprini Score greater than seven.[7] Standard anticoagulation regimens with enoxaparin (Lovenox) start injection within 6 to 8 hours after surgery and continue with 40mg subcutaneously daily for approximately 7 days.[8] Alternative regimens include taking a baby aspirin (81mg) once a day for 30 days or taking apixaban (Eliquis) 2.5mg twice a day for 7 days or fondaparinux (Arixtra) 2.5mg subcutaneously once a day

Continued on page 24

for 7 days.[9] Other recommendations include not adding routine chemoprophylaxis for non-risk patients.

The majority of patients will first be placed in the prone position for liposuction of the hip rolls. Proper padding, warm tumescent fluid and heated blankets are essential. Fat harvested for grafting should be grafted as soon as possible to enhance fat graft survival. Contouring the hip roll region first allows for a shorter abdominoplasty incision and improved body contour.

Blocking pain directly in the operative field is essential for decreased pain in the post-operative period by injecting either Marcaine with epinephrine and/or liposomal bupivacaine (Exparel) into strategic areas on the abdominal wall. Liposomal bupivacaine can provide pain relief for up to 72 hours. For example, intercostal nerve blocks from T 7 – T 12, ilioinguinal, iliohypogastric, para-rectus, rectus sheath, and transversal abdominal plane blocks are critical for patient recovery. Patients had less pain overall, required fewer narcotics, spent less time in recovery, had less nausea, and resumed normal activities faster than the control group without nerve blocks.[10] An important point is to not use lidocaine with liposomal bupivacaine as this inactivates liposomal bupivacaine.

The TAP block can be done preoperatively by the anesthesiologist using ultrasound guidance. In the abdominal field, a 1 cm incision is made over the anterior rectus sheath at the level of the umbilicus on each side. Blunt dissection is performed between the internal oblique muscle and transversalis muscle. A narrow and rigid tumescent fluid infiltration cannula is then used to inject a local anesthetic in a cranial and caudal direction. For example, 20 mL of liposomal bupivacaine can be mixed with 80 mL of saline creating 100 mL solution and 50 mL of this solution can be used for tap blocks on each side.

The planning and execution of a standard abdominoplasty remain unchanged. The incision should be placed 5 to 7 cm above the anterior labial commissure. It should extend 1 to 2 cm above the inguinal crease on either side. Plan incisions according to any hip asymmetry. The umbilicus should be placed midline at the linea alba at the level of the iliac crests or slightly lower, creating an inverted U or V is the most common technique. Half of all surgeons secure the umbilical dermis to the rectus fascia. The recent popularity of the lipoabdominoplasty has brought forth key patient safety issues. These include liposuction of the hip rolls and flanks and liposuction of the abdominoplasty flap itself which provide better contour to the overall result. It is essential to preserve the peri-umbilical perforators with limited undermining during the lipoabdominoplasty (no more than 2 cm). Leave a thin layer of fat on the abdominal wall fascia (no more than 2 cm). The diastasis rectus can still be repaired effectively. Quilled sutures work well. A no drain abdominoplasty is possible using progressive tension sutures. Quill sutures are placed in the midline and paramedian positions which takes tension off the final suture line and decreases seroma formation. The key technical components include limiting the dissection above the umbilicus and keeping the midline dissection from the umbilicus to the xiphoid 5 to 7.5 cm from the midline on either side to preserve the large perforator vessels. Liposuction should be confined below Scarpa's fascia especially in the supraumbilical region to avoid skin flap necrosis. Avoid laser assisted liposuction in the region of the lateral and central abdomen as this has been reported to have a higher rate of complications including skin necrosis.

Abdominoplasty is often combined with other procedures (most commonly liposuction) and this can be done safely; however, the risks are greater. Data from 25,478 abdominoplasties, of which 65.0 % were combined with other procedures, showed a 4.0 % overall 30-day complication rate, compared with 1.4 % for other aesthetic procedures.[11] Abdominoplasty can be performed safely with other procedures and it is recommended to keep the total operative time to less than 8 hours.

REFERENCES:

1. Rosenfield LK, Davis CR. Evidence-based abdominoplasty review with body contouring algorithm. *Aesthetic Surg J.* 2019, Vol 39(6) 643-661.
2. Batac J, Hamade M, Hamade H, Glickman L. Abdominoplasty in the obese patient: Risk versus reward. *Plast Reconstr Surg.* 2019 Vol 143(4) 721e-726e.
3. Rosenfield LK, Operating room checklist. *Aesthetic Society News*. Vol 23, 103-106 • Summer 2018

FERNAU CONTINUED

4. Fernau J. Recommended preoperative decolonization protocol. International Society of Aesthetic Plastic Surgery. Patient safety recommendations Issue Date 20 December 2016
5. Fernau J. The ERAS protocol for improving patient safety. *Aesthetic Society News*. Vol 23, Number 1;84-87 • Winter 2019
6. Pannucci CJ, Swistun L, MacDonald JK, Henle PK, Brooke BS. Individualized venous thromboembolism risk stratification using the 2005 Caprini score to identify the benefits and harms of chemoprophylaxis in surgical patients:A meta-analysis. *Ann Surg*. 2017;265(6):1094-1103.
7. Boundreault DJ, Sieber DA. Getting the best results in abdominoplasty: Current advanced concepts. *Plast Reconstr Surg*. 2019;3:628e-636e.
8. Vasilakis V, Klein G, Trostler M, Mukit M, Marquuez J, Dagum A, Pannuci C, Khan S. Postoperative venous thromboembolism prophylaxis utilizing enoxaparin does not increase bleeding complications after abdominal body contouring surgery. *Aesthetic Surg J*. 2020:1-7.
9. Sarhaddi D, Xu K, Wisbeck A, Deigni O, Kaswan S, Prada C, Lund H. Fondaparinux significantly reduces postoperative venous thromboembolism after body contouring procedures without an increase in bleeding complications. *Aesthetic Surg J*. 2019;39;11:1214-1221.
10. Feng LJ, Painless abdominoplasty: The efficacy of combined intercostal and pararectus blocks in reducing post-operative pain and recovery time. *Plast Reconstr Surg*. 2010;126:1723-1732.
11. Gupta V, Winocur J, Rodriguez-Feo C, et al. Safety of aesthetic surgery in the overweight patient: Analysis of 127,961 patients. *Aesthet Surg J*. 2016;36:718-729.

KAZEI CONTINUED

Cosmetic surgery is a unique subset of plastic surgery in which procedures are not medically necessary, and it is clear that different countries have widely varying attitudes towards this phenomenon. Multiple aspects could account for these differences; for example, religious backgrounds or cultural views on surgery could have major impacts on a nation's opinion. However, as different as these countries may be, they all teach plastic surgeons how to perform cosmetic procedures, which seems to illustrate the presence of a demand for these surgeries. The aim of this study is to determine the current trends of cosmetic procedures undergone by plastic surgeons themselves and compare them internationally. Additionally, we hope to answer the question: do plastic surgeons have a different view on cosmetic procedures when compared to their countries' citizens?

We hope to publish the results of this survey as soon as possible.

If any *ISAPS News* readers have questions or would like to be alerted when the survey results are published, please do not hesitate to contact us.

(E-mail: SurveyPlastSurg@bidmc.harvard.edu)

1. Surgery ISoAP. ISAPS International Survey on Aesthetic/Cosmetic Procedures 2018 [Available from: https://www.isaps.org/wp-content/uploads/2019/12/ISAPS-Global-Survey-Results-2018-new.pdf.
2. Gurunluoglu R, Gurunluoglu A. Do plastic surgeons have cosmetic surgery? Plast Reconstr Surg. 2009;124(6):2161-9.
3. Moayer R, Sand JP, Han A, Nabili V, Keller GS. The Prevalence of Cosmetic Facial Plastic Procedures among Facial Plastic Surgeons. Facial Plast Surg. 2018;34(2):220-6.

PATIENT SAFETY

PRIORITIZING PATIENT'S SAFETY IN BRAZILIAN BUTT LIFT (BBL) SURGERY: THE ADVANCED SAFE BBL USING WIRELESS ULTRASOUND DEVICE

MEHMET VELI KARAALTIN, MD - TURKEY

The fat transfer buttock augmentation or Brazilian Butt Lift (BBL), as it is commonly known, has become one of the top-ranking aesthetic procedures worldwide. However, plastic surgery societies have voiced concerns over the heightened risk of fat embolism with this procedure and have issued warnings.

Recently, a multi-society task force (that includes ISAPS, ASAPS, and ASPS) has funded a study and issued a corresponding patient safety advisory.

The Task Force hypothesizes that complications result from high-pressure extra-vascular grafted fat entering the circulation via tears in the large buttock veins resulting in pulmoner embolism.

Because no records or evidence has as yet shown a case of complication with fat only injected in the subcutaneous space (the space between the muscle layer and skin), the Task Force advisory relates to deeper injections (i.e., those to the muscle or under the muscle), which have led to the complications.

The advisory strongly recommends that surgeons keep the gluteal fat injection level under the skin and above the muscle level. Taking into consideration the advisory twelve months ago, I launched a clinical application called the Real-Time Ultrasound Assisted gluteal fat grafting.

This application entails simultaneous use of a wireless ultrasound Doppler probe placed on the buttock skin when the cannula is introduced in order to scan and identify the tissue layers as well as the vessels. As the fat injection commences, the ultrasound images projected wirelessly onto a screen allowing the surgeon and assistants to follow the planes where the cannula is introduced in order to avoid the danger zones.

Initially, the surgical markings are lined into four gluteal quadrants and the four cutaneous gluteal perforators are verified (by the aid of the doppler mode) and located respectively.

Afterwards, the injection cannula is introduced though an incision located at the superior aspect of the intergluteal crease (Figure 1). With the simultaneous use of the USG probe, the cannula is identified by its acoustic shadow.

The navigation is started as the tissue layer images from deep to superficial (muscle to skin) is projected wirelessly

to a mobile interface screen (Figure 2). Fat injection is then performed in several planes to the area between skin and muscle.

This technique was used on 68 patients in the last year with no complications. The Wireless Ultrasound is a user-friendly device with an easy and short learning curve. I recommend the use of the Wireless Ultrasound device for maximum patient safety during gluteal fat transfer.

Figure 1 – The figure shows the bi-manual approach of the surgeon during the fat injection process. The probe is draped in a sterile cover and placed parallel to the direction of the cannula. The surgeon checks the level of the cannula though the monitor display.

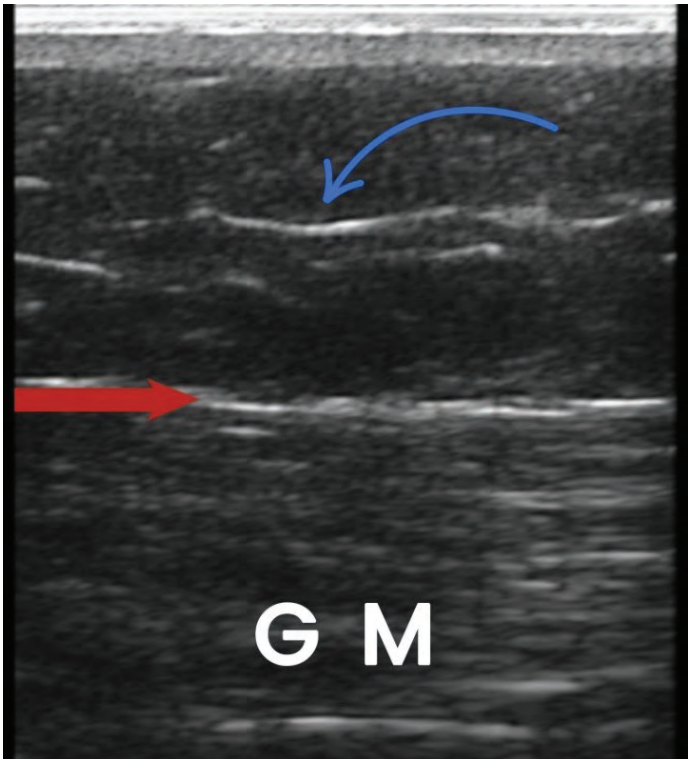

Figure 2 – A screen shot from the ultrasound scan monitor. The scan mode is set to biopsy, the red arrow shows the muscular aponeurotic layer separating (GM: Gluteus Maximus muscle) the adipo-facial layer from the muscular layer. Blue arrow points out the linear acoustic shadow of the inserted cannula.

Silgel™ Clearly better
By GC Aesthetics™

PROVEN

Welcome to Silgel™

The healing power of silicone for scar management.

From the global experts in silicone, GC Aesthetics.

www.gcaesthetics.com

Available again in May 2020

GC Aesthetics™

ISAPS JOURNAL

MESSAGE FROM THE EDITOR-IN-CHIEF

BAHMAN GUYURON, MD – UNITED STATES

I hope you are as eager to attend the 25th World Congress of ISAPS in Vienna as I am. I also hope that you have been preparing some presentations and have submitted an abstract. If so, I look forward to submission of your manuscript to your Aesthetic Plastic Surgery journal.

While subscriptions have increased almost 20% thanks to many of you, our team has kept up with the review process and in fact we have reduced the review time. The increase in submission has occurred in spite of limiting the journal articles to aesthetic topics only. The invited discussions may cause slight delay in publication; however, I hope you agree that these add value to the articles by including the opinion and interpretation of experts in the field.

Your journal continues to have the highest distribution amongst the aesthetic surgery journals and is read by international subscribers, creating global appreciation of your hard work. Most readers realize how much is involved in coming up with an idea, conducting research, analyzing the results, writing the manuscript, putting together the artwork, obtaining consent from patients, writing the legends, including the appropriate references, and submitting the article. This process requires time and commitment and we salute all of you for devoting the time and energy in sharing this hard-earned information with plastic surgeons internationally.

One of the cardinal reasons that I am personally looking forward to the Congress is a session on migraine surgery. You may be aware of my passion for this field and how I am destined to disseminate the knowledge garnered over the last 20 years through studies that our research team and others have conducted. You may be aware that the entire field of migraine surgery is the spinoff of aesthetic procedures. Considering that nearly one out of 5 female patients has migraine headaches and that the overwhelming majority of aesthetic surgery patients are females, the relevance of this presentation and its connection to aesthetic surgery becomes clear. This session will include a highly respected and internationally renowned neurologist who will discuss the basics of migraine headaches. Experts who have embraced this field will review the pertinent anatomy, means of detection of the trigger sites, and the entire gamut of the surgical techniques. These procedures are designed to deactivate the migraine trigger and most are common aesthetic procedures with some minor nuances. Incorporating these minor changes in the planned cosmetic procedure for patients who also suffer from migraine headches may not only give them a better appearance, it may also offer them relief from disabling headaches. I hope you will be able to take advantage of this opportunity.

ABDOMINOPL

ADRIANA POZZI, MD – ITALY
ISAPS National Secretary for Italy

GLOBAL PERSPECTIVES

LIPOABDOMINOPLASTY WITH UMBILICAL TRANSPOSITION

Traditional abdominoplasty has evolved over the years. We have moved from conventional procedures to techniques that combine liposuction and permit us to improve body contouring by treating lipodistrophies in the epigastric areas, pubis, and flanks. Furthermore, deeper knowledge of abdominal anatomy has made surgeons aware of the importance of saving vascularization on the lateral thorax. The superficial fascia system repair and the strategies used to close the dead spaces - described by Baroudi and Pollock - have dramatically diminished the incidence of seroma.

PROCEDURE

We generally perform the bicycle handle bar design as described by Baroudi. In our institution, general anesthesia is usually used with intraoperative intermitted pneumatic compression stockings to prevent thrombovenous embolism.

With the patient in supine position and slight hiperextension, the infiltration of the abdomen is started with superwet technique, saline solution with epinephrine 1/500.000, removing the lidocaine component. Liposuction is made behind the superficial fascia in the hypogastrium; while in the epigastrium the plane is both deep and superficial to allow release of the superior abdomen. The bicycle handle bar incision is made above the pubis and a very superficial undermining is made to respect the lymphatics.

Undermining is guided by the thin layer of jelly tissue, over the deep fascia, left by liposuction. In the epigastric area,

ASTY

complete undermining is limited to a medial tunnel of about 7/8 cm, sufficient for rectus repair. A discontinuos liposuction undermining is carried out laterally; this helps to preserve intercostal vessels vascularization, as recommended by the study of Dr. Alan Matarasso.

The design of the plication with horizontal lines permits a symmetrical approximation of the fascia. The plications are realized with 2/O PDO bidirectional barbed continuous sutures which let us control tension and tissue approximation and let us correct severe diastasis, with no knots and with no need for our assistant to maintain the flaps in tension. And so it is very effective and quick.

At the end of the suture, approximation is perfect and uniform under palpation. Quilting sutures, between the superficial and the deep fascia, are placed to close the dead spaces of the epigastric areas. The new umbilical site is positioned flexing the operating table and the new position is determined, usually 1-1.5 cm above the umbilicus stalk.

The design of the new umbilical site resembles a three-pointed star and the skin island of the umbilicus resembles a clover. Figure 1. This elegant technique allows us to get a little and natural navel. In the hypogastrium, paraumbilical sutures are placed and the excess skin is removed. Wound closure is done at three levels: superficial fascia, dermis and skin. No drains are positioned.

The pneumatic compression is maintained at all times when the patient is not ambulating and low molecular weight heparin in administered as home therapy. This technique allows a patient to have a safer and faster recovery time.

According to the AICPE survey, Abdominoplasty is the fifth most requested aesthetic surgery in Italy, with 21,800 annual procedures registered in 2018, + 21% comparate to 2016.

Figure 1 – This was a secondary case; the patient was operated on with the classic technique.

Figure 2 - The patient after a lipoabdominoplasty.

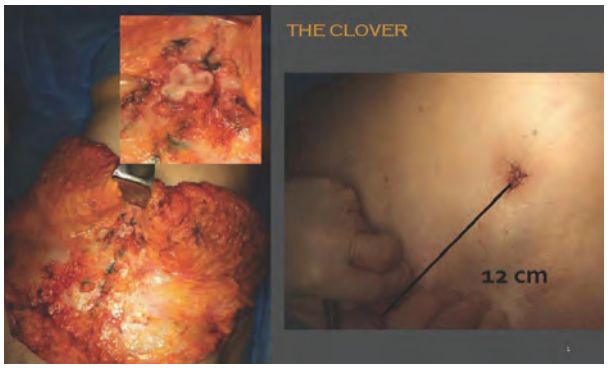

Figure 3

DRAINLESS LIPOABDOMINOPLASTY

GUSTAVO JIMÉNEZ MUÑOZ LEDO, MD – MEXICO
ISAPS Assistant National Secretary for Mexico

INTRODUCTION

Abdominoplasty is one of the most common procedures performed by plastic surgeons worldwide, according to the ISAPS Global Survey for 2018. It is the fourth most common surgical procedure.

Surgical techniques have changed over time involving more aggressive liposuction nowadays in combination with fat grafting.

TECHNIQUE

I present our surgical technique that has been useful in achieving superior results with lower downtime and improving the comfort of our patients.

First, we mark the patient. We ask her to bring smaller underwear than she usually wears to ensure that the incision will be always be inside the panties. We mark her standing and prone in the areas where we will do liposuction and the areas of lipo-grafting.

Then under general anesthesia, we infiltrate with tumescent solution (3L of Hartmann with 3 ampules of epinephrine and 1 ampule of 7.5mg of ropivacaine). Then we do a super wet liposuction and harvest the fat in case we want to use it for lipofilling of the buttocks. We prepare this fat with decantation and add two antibiotics (amikacin and cephalotin), then we incise according to our marking, raising the flap and making a small tunnel going up to the xiphoid. We mark the rectus abdominus fascia plicature and perform this with 1 prolene and x inverted separate stitches. We tailor our skin flap and excise the excess skin, marking where we want to exteriorize our belly button with an inverted v incision.

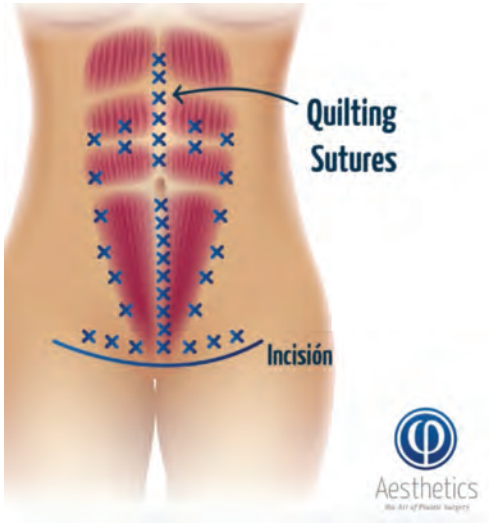

Figure 1 – Quilting sutures used to fin the flap of abdominoplasty.

Finally, we start fixing our flap to the abdominal sheath with quilting sutures using 2-O monocryl on the muscular borders of the rectus and linea alba as showed in the figure.

With these sutures, we fix the flap to the abdominal wall, ensure that there is no negative space, and add less tension to the closure because it distributes over the stitches so that it gives us a superior result. With this maneuver, we don't need to use a drain. The incision is closed in three layers: a running suture with 2-O monocryl on Scarpa's fascia, then a dermis closure with 3-O monocryl separating stitches, and a running intradermal suture with 3-O monocryl for skin. We exteriorize the belly button through the inverted v incision and perform a vertical bottom incision on the original belly button to fit the inverted t.

Finally, we do fat grafting of the buttocks and hips in the subcutaneous space if it's planned.

The patients spend their first night in the hospital and we encourage them to walk in the first hours post-surgery. The next day, they take a shower in the hospital and use soft compression garments and foam. We schedule post-op visits at 8, 14, 30 and 60 days to review. We send them to external ultrasound and they have manual lymphatic drainage with a therapist beginning on the fourth postop day.

RESULTS

Here are some pre and post op photos.

Figure 2 – Above pre-op pictures; bottom 30 days post-op.

Figure 3 - Above preop, bottom postop 30 days; we also performed a subfascial breast augmentation with 300cc round smooth implant.

Figure 4 - Above preop; bottom 30 days postop

FIRE & ICE PROTOCOL

A NOVEL APPROACH IN NON-INVASIVE BODY CONTOURING

SERGIO E. AYUZO-DELVALLE, MD – MEXICO

HAROLD M. DENT-ALVARADO, MD – MEXICO



DAVID F. NAVARRO-BARQUIN, MD – MEXICO

ROGELIO MARTINEZ-WAGNER, MD – MEXICO

Introduction: Non-invasive body contouring is a fast-growing, high demand aesthetic procedure and a variety of medical technology is available on the market that is focused on creating lipolysis in specific areas with the least down time possible.

Cryolipolysis is one of the most popular and proved to be an effective method to focally reduce subcutaneous fat tissue. Most studies have addressed the reduction of the fat layer by ultrasound measurements obtaining an average of 15-20% reduction, and a few have addressed circumferential changes, with good overall satisfaction by physicians and patients.

Focalized radiofrequency is another fast-growing technology for tightening the skin, that has gained popularity by achieving reliable results in tightening specific areas of the body without significant adverse effects, and has been quantified basically by using circumference measurements.

Although these technologies have been proven to be useful, reliable and safe and achieved body contouring by different mechanisms, most of the studies have focused on one technology and haven't taken advantage of the potential effect of mixing these technologies - or taken advantage of volume reduction using cryolipolysis and skin tightening by radiofrequency to enhance body contouring results.

Methods: A prospective study was conducted from January to November of 2019 in a private practice clinic (Clinic Mexico Aesthetic Surgery Specialists) with 100 patients in whom the Fire-Ice Protocol was applied.

This protocol consisted of one session of cryolipolysis (using CoolSculpting®) in at least one anatomical area, and after a six-week rest period, followed by three sessions of radiofrequency (Exilis Elite®) for another three-week period. Results were evaluated in a dual approach: measurements and volume were quantified using CRISALIX®. Ultrasound measurements of the treated area, and standard perimeter measurement of the treated area after three months, and by two independent physicians, were addressed. Demographic data (age, sex and weight) were also recorded as well as the overall satisfaction of the patient. Statistical analysis was conducted using SPSS 21® for Mac.

Results: Preliminary results suggest an increased patient satisfaction above 90% with assessment of applying this protocol to other areas; the independent panel has reported 70% good result, 15% excellent, and 15% with no visible change. CRISALIX measurements, anthropometrics and abdominal wall ultrasound are still in process.

Conclusion: The data is encouraging; however, definitive results are still pending to report final conclusions.

The authors have no financial interest in any company or product mentioned in this article.

UMBILICAL REINSERTION IN ABDOMINOPLASTY

MAZEN BDOUR, FRCS(ED.) – JORDAN
ISAPS National Secretary for Jordan

The umbilicus is the center of the circle in the drawing of Vitruvian Man by Leonardo da Vinci.

A prominent scar on the abdomen, it is your first ever scar and the only naturally occurring scar in the human body. Its position is relatively constant on the mid-abdomen line at the level of the iliac crest.

The umbilical tip, which is the scar left by detachment of the cord, is the center of the umbilicus.

Around the cord remnant is the umbilical collar, formed by the dense fibrous umbilical ring. Surrounding the umbilical collar is the umbilical skin.

As a scar, the umbilical has different forms:

Figure 1 – Outie: The umbilical tip protrudes past the peri-umbilical skin causing a protruding umbilicus.

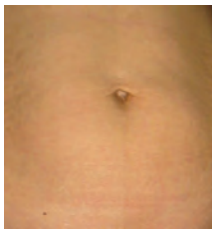

Figure 2 – Innie: The umbilical tip doesn't protrude past the peri-umbilical skin causing a concave umbilicus.

Figure 3 – Distorted: Any umbilicus which doesn't fit either of the afore mentioned categories.

In the past, a bare navel was considered taboo, but times have changed and exposing the umbilicus has become common practice among young men and women.

There are no particular standards to define what is an aesthetically pleasing umbilicus. But in general, the T concave, small umbilicus with superior hooding scores the highest in aesthetic appearance in literature. Whereas the presence of any degree of protrusion and a horizontal orientation or distorted shape is considered a less than pleasing aesthetic result.

As abdominoplasty is still one of the top aesthetic surgery procedures, an aesthetic umbilicus is a vital component of patients' satisfaction. Poor results can ruin an otherwise successful abdominoplasty.

Many different techniques may be used to reinsert the umbilicus with the main purpose being to create an aesthetically accepted umbilicus.

I have been using a particular technique since 1995, and I presented it at the 7th Congress of Pan Arab Association for Burn and Plastic Surgery held in Jordan in April 2001.

The abdominal flap is raised, the extra skin cut, and the flap is then closed using staples. A circle is drawn centered on the site of the new umbilicus with a diameter almost the size of the circumcised umbilicus.

An inverted V-shape is marked, with a slight curved tip, with its base inferiorly between 4-8 o'clock and its apex between the center of the circle and 12 o'clock. Usually the length is between 12-20 mm depending on the thickness of the panniculus. The skin is then de-epithelized 2mm along the marking then cut along the inferior part of the de-epithelized skin, leaving the de-epithelized skin with the abdominal flap.

The abdominal flap is lifted and the marked circle is partially defatted

A triangle of the umbilicus is excised between 4 and 8 o'clock with its apex at the center. The opening in the abdominal flap should be sufficient to pass your index finger through it.

Continued on page 36

In post bariatric surgery, the umbilical stalk is usually long. Shortening it establishes depth and hides the closure of the umbilicus on the abdominal flap. (Figure 4)

Figure 4 – Abdominoplasty post Bariatric surgery pre and post-operative view.

Three stitches are used to anchor the abdominal flap around the umbilical insertion site to the rectus sheath using prolene 3/O.

The apex of the inverted V abdominal flap with the umbilicus center is sutured to rectus sheath.

The other two stitches at 2 and 10 o'clock at the abdominal flap, passing the needle through the opening in the abdominal flap through the scarpus fascia, back to the de-epithelized skin and again through the de-epithelized skin, 3mm away, down to the scarpus fascia.

The abdominal raised and the two stitches at 2 and 10 o'clock are pulled from inside and anchored to the rectus sheath at 3 and 9 o'clock around the umbilicus. (Figure 5)

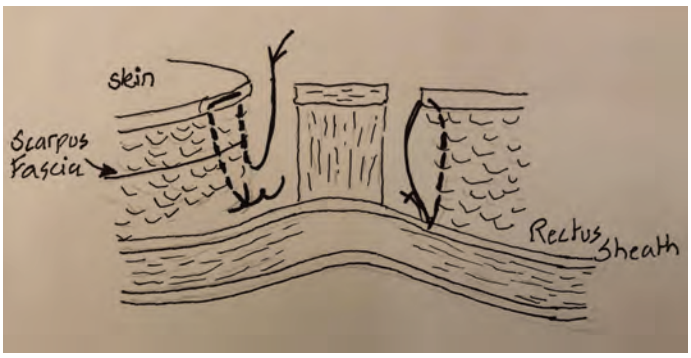

Figure 5 – Anchoring the abdominal flap to the rectus sheath

Before tightening the three anchoring stitches, the umbilicus is pulled out through the opening in the flap. The inverted V abdominal flap is sutured to the umbilicus, where the wedge is excised, using 3/O vicryl. Then the three anchoring prolene stitches are tightened. This will fold the peri-umbilical abdominal flap skin inward.

The umbilicus is tailor cut, if needed, to fit into its new position in the abdominal flap.

A few interrupted vicryl 3/O stitches are applied to fix the umbilical stalk to the scarpus fascia. This will prevent umbilical protrusion.

The umbilicus is then sutured to the de-epithelized abdominal skin by half buried prolene 4/O transverse mattress stitches with the knot on the umbilical side.

Anchoring the abdominal flap, two points laterally and one inferiorly allows creation of the aesthetic superior hooding of the new umbilicus giving it a naturally youthful look. (Figure 6)

The use of the inverted V-shaped flap also helps avoid scar contracture and gives concavity as in a normal umbilicus. (Figure7)

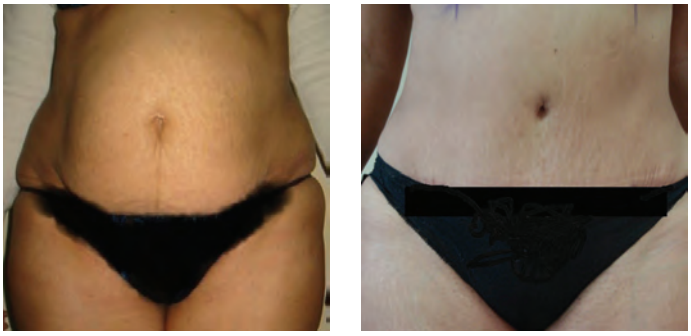

Figure 6 – Pre and post abdominoplasty view showing the superior hooding.

Figure 7 – Pre and post abdominoplasty view showing the concavity of the umbilicus.

ABDOMINOPLASTY

A THREE-DIMENSIONAL APPROACH

MARIA ISABEL CADENA, MD - COLOMBIA
ISAPS National Secretary for Colombia

INTRODUCTION

The characteristics of a female silhouette are a harmonic and natural relationship of her curves. This relationship can be affected by bone structure, pregnancy, weight changes, aging and previous surgical procedures. To recover or create these curves **mixed methods** are usually required: liposculpture and abdominoplasty. Together, these methods together create harmony between the different structures. In this regard, three concepts must be developed: 3D projection of the flanks, waist to hip relationship and recovery of the abdominal zone.

In 2001, Saldanha popularized lipoabdominoplasty as a method of improving the body contour (*Ref 1*). It is one of the most commonly performed procedures, was the number one procedure in 2017, and liposuction was fifth in the same year according to ISAPS Statistics. (*Ref 2*).

In my fifteen years of experience, I have been modifying my concepts and surgical techniques to achieve the proposed objectives.

DIAGNOSIS

Include complete medical records, anthropometric measurements, pre-surgical laboratory exams.

In the physical examination, my approach is tridimensional. I observe the proportion of the body between its superior and inferior half. I touch the diastasis level of the abdominal muscles, looking for abdominal wall hernias. Then, I redefine the waist to hip ratio, which should be approximately 0.65. I place the new location of the waist, usually found at the lower edge of the navel, and draw an imaginary a circumference line at the new position of the waist. I identify the fat located on the flanks in three projections (anterior, lateral and posterior) (*Figure 1*), locate liposuction and fat grafting areas, and finally I measure the excess skin to be removed from the abdomen and the final position of the scar keeping this in the medical chart as the surgical plan.

INDICATIONS AND CONTRAINDICATIONS

Figure 1 – 3D Projection of the flanks, (anterior, lateral and posterior).

The candidates for these procedures are women with bodies that, for multiple causes, have lost the waist-to-hip relationship, as well as patients with rolls at the flanks and who have an excess of skin in the superior or inferior abdomen. Additionally, patients with chronic diseases under adequate medical control may be considered for this procedure.

Active smoking, current oral contraceptive use, Lupus, obesity, and thrombosis history are contraindications for using mixed methods.

PREOPERATIVE PREPARATION AND PLANNING

It is fundamental to recall that lipoabdominoplasty requires the attention of multiple factors to ensure patient safety that

Continued on page 38

include: clinical chart, medical history, surgery planning, number of procedures, Caprini assessment, thromboprophylaxis and evaluation of suitable antibiotics for prophylaxis.

In the immediate preoperative assessment, with the patient in bipedestation, I mark the rolls areas (*Figures 2, 3*), depression

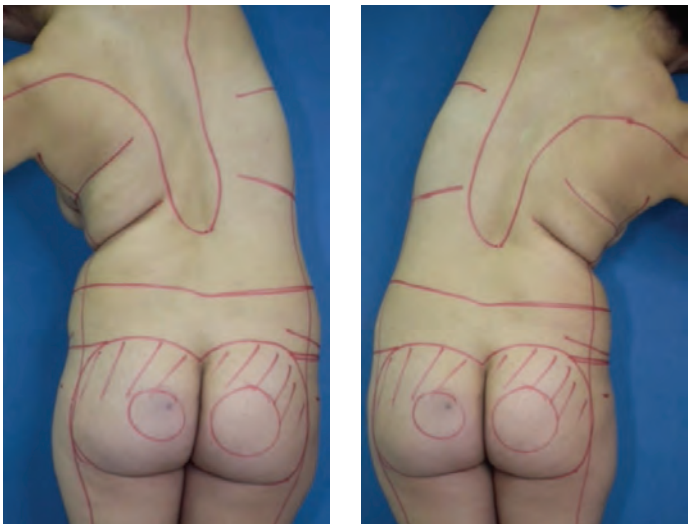

Figure 2 and Figure 3 - Roll areas.

zones and evaluate buttocks shape, locate the current and future waist (*Figure 4*), zones of lipodystrophy for liposuction (*Figure 1*), mark the fat grafting areas (*Figure 5*), paint the abdominal flap to remove, evaluate the position and design of the new umbilicus, and finally I paint the position of the new scar. (Using the 7's law, the inferior scar must be about 6 or 7 cm from the vulva.) (*Figure 6*).

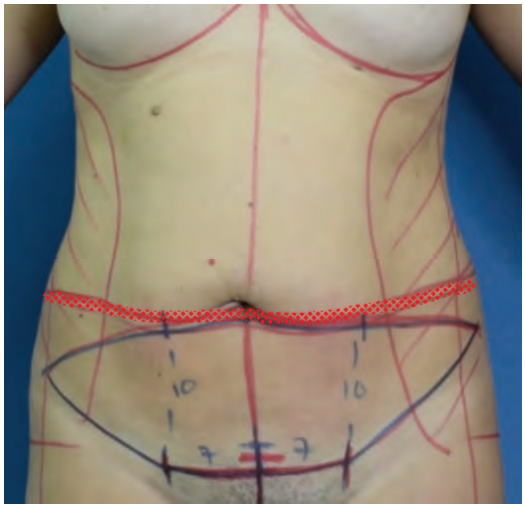

Figure 4 - Locate the current and future waist.

SURGICAL TECHNIQUE

Most of the maneuvers I use are very similar to the literature described (*Ref 3*). I will explain the techniques that I have been modifying through the years of my practice. Indeed, mixed methods require liposculpture and abdominoplasty, which includes three points: 3D Projection of the flanks, recover waist to hip relationship and improve abdominal zone (plication of abdominal wall, remove excess skin, relocate, design the new umbilicus and draw the location of the scar).

Figure 5 – Fat grafting in gluteal area and lateral areas, also lipodystrophy at the back and flanks.

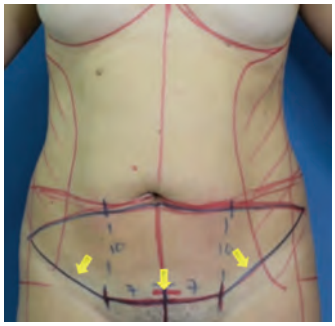

Figure 6 – Paint the abdominal flap to remove and position of the new scar.

First, infiltrate tumescent solution with a multi-hole cannula, according to the area that I am going to work on. Use 1000 ml of normal saline and 2 ampoules of epinephrine in a 2:1000 ratio. Approximately 4000 ml and 5 minutes of waiting time for vasoconstriction is needed.

Second, I do liposuction in the lipodystrophy areas in three positions: lateral (for each side), supine and prone. This is the key to body contouring and creation of new female curves.

In the rolls areas, it is important to dissect the septum between the tissue. I use multiple cannulas of different lengths with diameters between 5mm, 4mm and 3.5 mm, with one side linear ports (to prevent skin necrosis) (*Figure 7*).

Figure 7 - Three port harvest cannula.

Every time that I change the position, repeat the asepsis with chlorhexidine and change the gloves.

Third, in a prone position, I check the pinch, do the liposuction refinement and fat grafting in the superficial plane of the buttocks

approximated 250 cc in every side. Be aware during fat grafting (*Ref 4*), to place it in a subcutaneous plane and avoid going deeper in the middle line, all this to prevent fat embolism.

Next, in the supine position the liposculpture of the flanks is finished, I close all ports. New asepsis and placement of operative fields are performed to begin the abdominoplasty. Incision of skin, flap dissection, tunnel dissection in the rectus plication area, plication of abdominal wall with non-absorbable monophylament 2-O is made, cut the inferior pole of the navel with Pavajeau's technique (*Ref 5*), position of the umbilicus is fixed with non-absorbable multyphilament 2-O (*Figure 8*). In some cases, it is necessary to do a neo umbilicoplasty technique, when the umbilicus is descended less than 7cm from the symphysis pubis.

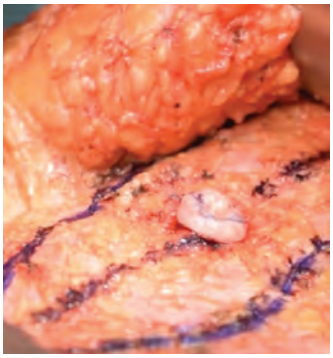

1Figure 8 - Rectus abdominis plication and design the naval with Pavajeau´s technique.

Placement of supraumbilical Baroudi stiches (*Ref 6*). Removal of excess skin (*Figure 9*). Replacement of the umbilicus and suture, confirm the symmetry of the final scar, and close in 3 layers with absorbable multyphilament 2-O, multyphilament 3-O and absorbable monophylament 4/O.

Figure 9 - Excess skin to remove.

Finally, vac drain system of 400 ml is placed (which is removed when production is less than 20 cc in 24 hours) and cure with chlorhexidine gauze dressing, gauze, micropore.

POSTSURGICAL CARE

To have successful results, I take care of 12 measurements in postsurgical care:

1. The patient remains in hospital for one day
2. Prophylactic antibiotic only
3. Regular diet
4. Pain control with elastomeric pump
5. Use a mesh, for a month
6. Lymphatic drains every day for 5 days
7. Chemical or mechanical thromboprophylaxis
8. Follow up every two days during the first week - go the doctor's office for clinical control
9. Remove the drain when it produces less than 20 milliliters in 24 hours
10. Back to work in 10 days
11. Driving at 2 weeks
12. Can start exercising at 6 weeks, gradually

POSTSURGICAL MEDICAL CHECK

I recommend a close follow-up. An early follow-up, at the first 12 to 24 hours to check the wound, hematoma assessment, and skin characteristics. A secondary follow-up at the medical office every three days for two weeks. Finally, a midterm control, every three to four weeks.

COMPLICATIONS

The most common complication is seroma. In my patients it is about 6% who usually resolve with one or two aspirations. I have 0% for chronic seroma and fewer cases for revision of the scar. Liposuction zones recover 100% sensation and all patients with abdominoplasty present dysaesthesia in the scar area.

CONCLUSIONS

Lipoabdominoplasty is a safe and effective procedure, in appropriately selected patients.

For a harmonious result in the lipoabdominoplasty procedure, it is important to reestablish:

1. The waist-to-hip ratio proportion.
2. The 3D projection of the flanks.
3. The body contourning.

And the follow-up is always mandatory.

Continued on page 40

SAMPLE BEFORE AND AFTER PHOTOS

Case 1: 30-year old patient, Caprini risk 4
Total Liposuction: 3500 cc
Fat Grafting in Buttocks 280 cc each side
Fat grafting in Hip: 150cc each side
Abdominal inferior flap Dermaolipectomy piece weighted 750grs.

Case 2: 36-year old patient, Caprini risk 6
Total Liposuccion: 3100 cc
I didn't use fat grafting
Abdominal inferior flap Dermaolipectomy piece weighted 1400 grs.

REFERENCES

1. Lipoabdominoplasty without undermining. Saldanha OR. Aesthetic Surgery Journal. November 2001. Volume 21. Issue 6.
2. ISAPS International Survey on Aesthetic/Cosmetic procedures performed in 2017.
3. Body contouring by lipolysis: A 5-year experience with over 3000 cases. Illouz YG. Plast Reconstr Surg 1983;72:591-597.
4. Nanofat Grafting: Basic Research and Clinical Applicactions. Patrick Tonnard, et al. Plastic and Reconstructive Journal. October 2013.
5. Umbilicoplastia en semicono: técnica para reducir al mínimo la cicatriz umbilical. Luis Pavajeau Muñoz. Revista Colombiana de Cirugía Plástica y Reconstructiva. Junio 2005. Volumen 11. Pag 29.
6. Abdominoplasty Hughes, C.Aesthetic Surgery Journal, September/ October 2002. 22(5), 465 473. doi:10.1067/maj.2002.129158

GLOBAL PERSPECTIVES: FUTURE THEMES

June 2020: Breast Augmentation
Deadline: April 15

September 2020: Otoplasty
Deadline: July 15

To contribute an article of 500-750 words, please forward it to ISAPS@isaps.org with the subject line: ISAPS NL Series. This should be a non-referenced opinion piece of several paragraphs giving your observations and perspectives on the topic. What do you do in your practice? What unique approaches do you use? What do you see your colleagues doing in your country or region? Photos are welcome, but must be high resolution JPG files attached, not embedded in your article. Please include photo captions.

Articles must be submitted as WORD documents.

PREOPERATIVE DIETING IN ABDOMINOPLASTY

FABIAN CORTINAS, MD – ARGENTINA
ISAPS Board Trustee
ISAPS National Secretary for Argentina

Postoperative pain control is the key for early deambulation after abdominoplasty and additionally deambulation is widely accepted as the best prevention for DVT. The mechanism of walking also improves fluid management in the early postoperative period, improving blood perfusion to the tissues and reducing swelling.

The increase of the intra-abdominal pressure (IAP) after abdominoplasty has been a topic of discussion and investigation for many years and addressed by several authors. Recent papers from Rodriguez, M. A. et al (1, 2) browse in detail the amount and consequences of postoperative incremental IAP.

The magnitude of intra-abdominal content must also be part of the equation. For the same patient, more intra-abdominal content, i.e., residual food, full bladder, will lead to a higher IAP in the immediate postoperative time and consequently cause of pain or increased discomfort which will trigger a cascade of events:

- superficial breathing (increasing choices of atelectasis)
- tendency to avoid changes of position and particularly deambulation
- full stomach sensation
- resistance to drink
- dehydration with the subsequent increase in blood viscosity, one of the components of the Virchow's Triad

Preoperative preparation for an abdominoplasty, in which a muscle plication will be performed, should include an approach to the intra-abdominal content that can be managed as in many sport disciplines.

To get a flat abdomen without content regular fasting is not enough. I strongly recommend 48 hours of preoperative dieting. The first component of this care is the reduction of proteins and fibers and in replacement an increase of the intake of fluids (juices, soups, water, tea). The daily amount must be around 3000 ml. Some small pasta dishes can be also part of the diet. Patients who suffer constipation must do a micro enema the day before.

As a result of this simple preparation, we will have a flat abdominal wall which can be mobilized for plication without tension and therefore with better postoperative comfort.

REFERENCES:

1. Preoperative Respiratory Physiotherapy in Abdominoplasty Patients. Rodriguez, M.A, Masako Ferreira, L, Nitz de Carvalho Calvi E, Nahas F. Aesth Surg J. 2018. 38(3), 291-299
2. Does the Diastasis Width influence the Variation of the Intraabdominal Pressure after Correction of Rectus Diastasis? Rodriguez, M.A, Nahas, F, Pacheco Reis, R, Masako Ferreira, L. Aesth Surg J 2015. 35(5) 583-588

TOO WIDE, TOO NARROW, TOO LATERAL, TOO LOW OR TOO HIGH

HOW TO DO THE UMBILICAL REVISIONS AFTER ABDOMINOPLASTY

GIANLUCA CAMPIGLIO, MD, PHD – ITALY
ISAPS 2nd Vice President

INTRODUCTION

According to recent ISAPS statistics, abdominoplasty is one of the most performed procedures worldwide. However, as for any other aesthetic operation, major or minor revisions can be required after 6-9 months. Among the latter, the refinements of the final size and/or position of the umbilicus are the most frequent.

The beautiful, natural and appealing umbilicus is no larger than 1.5-2.5 cm, usually has a cylindrical shape with a wide attachment to the abdominal wall fascia, and presents a central mamelon. Pregnancies and aging can modify its shape or size. It is flat and vertical in young, nulliparous patients and becomes hooded with a transverse appearance in multiparous women.

TOO WIDE

In some cases, the umbilicus is enlarged due to excessive tension at its edges. For minimal widening, the size of the umbilical scar can be reduced removing two skin triangles from its upper half as shown in Figure 1. When the defect is larger, the decrease of the dimensions is obtained by removing the peripheral scar and three big cutaneous triangles from the navel as shown in Figure 2. Sutures are removed after 10 days.

Figure 1-a *Figure 1-b* *Figrure 1-c*

Figure 1 - Planning of the removal of two skin triangles from the upper half of the navel (Fig.1-a), sutures of the two gaps (Fig.1-b) and appearance of the navel after stitches removal (Fig.1-c).

Figure 2-a *Figure 2-b* *Figrure 2-c* *Figure 2-d*

Figure 2 - In case of significant enlargement of the umbilicus, the removal of dystrophic peripheral scar and three big skin triangles is planned (Fig.2-a). The skin triangles (Fig.2-b) and then the peripheral scar are removed (Fig.2-c). Sutures of the wound margins (Fig.2-d).

TOO NARROW

A narrow and stenotic umbilicus is usually the consequence of poor relocation during the abdominoplasty or of a hypertrophic circular scar. Many techniques of umbilicuplasty try to prevent this complication breaking the line of skin incision and/or interposing local flaps. If the navel is narrow or becomes narrower in the post-operative period, an effective trick is to use a small marble, similar to one used by the children to play. It has to be applied with tape and maintained 23 hours per day for at least 3 months (Figure 3). If this physiotherapy is unsuccessful, a surgical revision is necessary and consists of removing a small strip of abdominal skin surrounding the umbilicus.

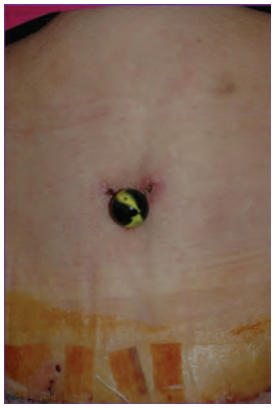

Figure 3-a

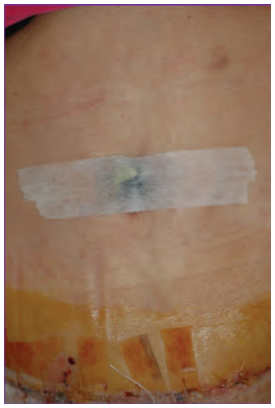

Figure 3-b

Figure 3 - A small marble can be used to stretch the umbilical scar and prevent or correct its stenosis (Fig.3-a). It is applied using a tape for 23 hours per day (Fig.3-b).

TOO LATERAL

Many techniques have been described in the literature to relocate the umbilicus after an abdominoplasty. The emersion of the umbilicus through the abdominal flap can be performed not exactly along the midline but slightly laterally. Great attention must be paid during this step of the procedure because in some patients the umbilicus stalk is not naturally placed along the midline (Figure 4). The correction of a laterally displaced umbilicus starts with a circular incision around the navel that frees it completely (Figure 5). A full thickness skin ellipse from the side toward which the umbilicus must be moved is removed. A resorbable stitch is used to reduce the length of the lateral hemi-circumference from the side where the umbilicus is shifted. Sub-cutaneous and cutaneous sutures fix the navel in its new position and the skin is closed.

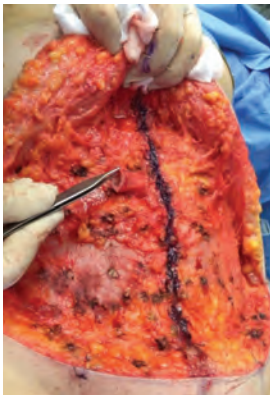

Figure 4 - In some patients, the umbilical stalk is not originally positioned along the midline but is displaced laterally.

Figure 5-a

Figure 5-b

Figure 5-c

Figure 5-d

Figure 5-e

Figure 5-f

Figure 5 - Planning of the revision of a laterally displaced umbilicus (Fig.5-a). The navel is completely freed and a small ellipse of skin from the side toward which the umbilicus must be shifted is removed (Fig.5-b). The umbilicus now can be easily moved toward the midline (Fig.5-c). The lateral hemi-circumference of the umbilicus is closed reducing its length (Fig.5-d). The umbilicus is fixed in its new position using dermal stitches (Fig.5-e). Final appearance of the umbilicus now correctly positioned along the midline (Fig.5-f)

TOO HIGH/TOO LOW

This is the most difficult complication to be corrected. If a navel is too low, and there is still some laxity from the abdomen, a secondary abdominoplasty can be performed removing the old umbilical scar with the skin excess, but this is a very rare situation. More frequently the abdomen is flat and the only way to move the umbilicus up or down is to relocate it leaving, inevitably, a vertical scar following the closure of the old umbilical site (Figure 6).

Continued on page 44

Figure 6-a

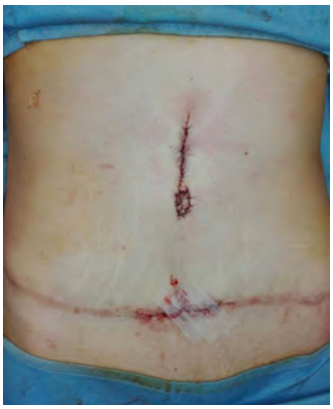

Figure 6-b

Figure 6 - The umbilicus has been relocated too high in a flat abdomen without residual skin excess. The new position of the navel is planned lower along the midline (Fig.6-a). Intra-operative result at the end of the procedure. The transverse abdominal scar has been also revised (Fig.6-b).

CONCLUSION

Revisions of the size or position of the umbilicus can be required after an abdominoplasty in order to obtain a satisfying result. The techniques listed above are effective in solving most of such problems and they can be performed under local anesthesia plus sedation as an outpatient operation.

REFERENCES

1. Hayati Akba, Ethem Guneren, Lufti Eroglu and O. Ata Uysal, Natural-Looking Umbilicus as an Important Part of Abdominoplasty, Aesth Plast Surg, 27:139; 2003
2. Rohrich RJ, Sorokin ES, Brown SA, Is the umbilicus truly midline? Clinical and medicolegal implications. Plast Reconstr Surg. 112:259; 2003
3. Joseph WJ, Sinno S, Brownstone ND, Creating the perfect umbilicus: a systematic review of recent literature. Aesthetic Plast Surg. 40:372; 2016

Italian ISAPS member Dr. Marco Stabile and his colleague Dr. Luca Rosato as they "fight in the first line in the Covid 19." Our heartfelt gratitude for this humanitarian effort by our friends - in their home country. Our sympathies to the Italian people and to so many others around the world who are afflicted with Corona Virus now.

WAIST DEFINITION WITH SUPRA SCARPA ABDOMINOPLASTY

HISHAM EL MINAWI, MD - EGYPT
ISAPS Assistant National Secretary for Egypt

Abdominoplasty is considered by patients as a state-of-the-art procedure that contours the body and brings back the old shape, removes the excess skin and fat, and eliminates stretch marks, if present, in the lower abdomen. The biggest concern of the patients after the scar, is the umbilicus and the waist.

One of the biggest challenges that faces surgeons is the shape of the trunk after abdominoplasty. Some patients complain that they lose the waist line while others consider some of the results unsatisfactory if the waist area is not well defined.

Figure 1 – Before and after showing the enhanced waist line.

The use of supra scarpa's dissection has reduced the incidence of seroma formation in cases of abdominoplasty remarkably. The technique used here is aimed to reduce the transverse diameter of the abdomen at the level of the waist by placating the fascia after the removal of a V shaped area of the fascia infra umbilical. By doing so, the waist can be reduced from 1-4 inches more than usual. The technique can be used in all cases of abdominoplasty – in slim and heavy patients.

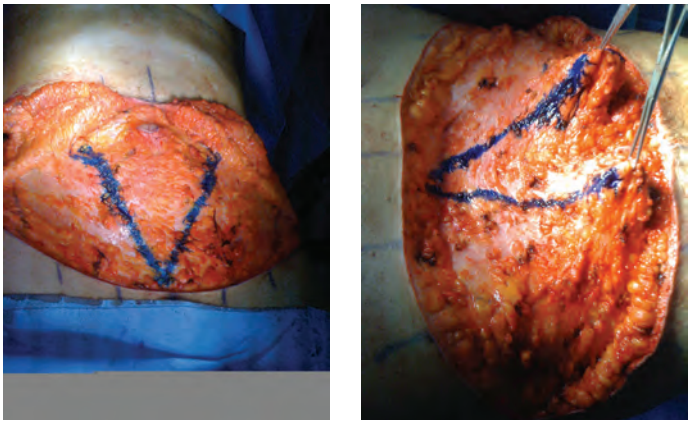

Figure 2 - The marking of the v shaped area of excision and lifting of the 2 lateral wings to plicate them in the mid line.

I started to use the supra scarpa's abdominoplasty more than twelve years ago initially to reduce seroma. Later I modified my technique and more than 900 cases were done which I presented at the ISAPS meeting in Russia in 2011, where I presented the transverse plication. Dr. Dirk Richter, our President, was presenting the vertical pull of the scarpa's fascia.

The technique also helps to reduce the scarpa's fascia infraumbilical removal of the thick middle potion of the fascia and pulling medially the thin fascia from the lateral part of the abdomen.

Continued on page 46

A lower transverse abdominal incision is done, then after dissecting the abdominal flap above the scarpa's fascia, up to the level of the umbilicus. The umbilicus is then dissected and cut through the skin, then the mid line is dissected in the middle line deep over the rectus sheath up to the xiphi sternum.

Below the umbilicus, a V shaped area of the scarpa's fascia is dissected and removed, then the medial edges of the fascia are undermined. After the midline plication of the rectus sheath, the scarpe's fascia is approximated and sutured in the mid line producing tension on the waist and lower abdomen, reinforcing the waist area.

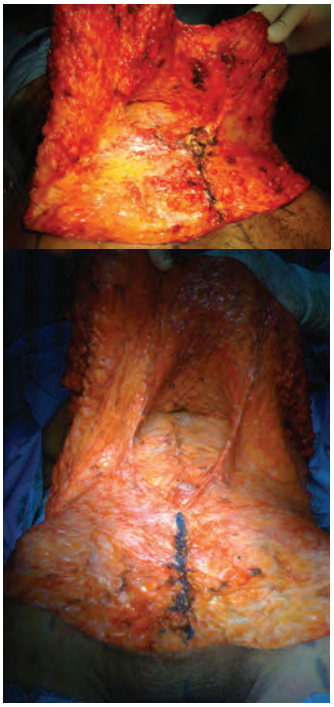

Figure 3 - Plication in the mid line, enhancing the waist.

The umbilicus, also one of the things that bothers patients, is also dissected using a circular incision. Then on the abdominal site of insetting the umbilicus an inverted v is drawn and incised; the umbilicus is pulled out and an inverted v is excised from the lower part of the umblical stump; the v shaped flap from the abdomen is sutured in place, making the scar concealed inside the umbilicus.

The technique, is a reliable easy way to re-define the waist area, and also by preserving the scarpa's layer, we reduce the risk of seroma and minimize the need to use drains.

Figure 4 - Before and after surgery.

Figure 5 - Umbilical scar.

Figure 6 - Before and after in a case of massive weight loss.

Figure 7 - Minimizing the waist from 1-4 inches.

Figure 8 - Pulling the 2 lateral wings to plicate them in the middle line.

DEVELOPMENT OF A SAFE, REPRODUCIBLE, AND TIME-EFFICIENT APPROACH TO ABDOMINOPLASTY

CHRISTOPHER D. FUNDERBURK, MD – UNITED STATES

ABRAHAM PATHAK, MD – UNITED STATES

BENJAMIN SHULTZ, MD – UNITED STATES

ALAN MATARASSO, MD – UNITED STATES
ISAPS Assistant National Secretary for the United States

INTRODUCTION

Surveys of plastic surgeons reveal that abdominoplasty procedures have been increasing in popularity over the last decade. The procedure is performed by approximately 93% of plastic surgeons in the United States. Over 150,000 patients underwent the procedure in the U.S. in 2018. Abdominoplasties generated nearly one billion dollars in a single year in the U.S. alone. This rise has been attributed to an increasingly health-conscious aging population and the youthful, slim ideal torso promoted in both traditional and social media.

Along with the increasing popularity of the procedure comes a need for a safe, reproducible and time-efficient technique on the part of the plastic surgeon. As part of the *Global Perspectives* series, this review focuses not only on the senior surgeon's current approach to abdominoplasty, which has been developed through years of experience, but also on the contributions of an international array of incredible plastic surgeons, both past and present.

PREOPERATIVE AND INTRAOPERATIVE PATIENT MARKINGS

Careful attention to patient markings is key to a symmetric, aesthetically-pleasing, and time-efficient abdominoplasty. Preferentially, the patient is marked the day prior to surgery in the surgeon's office. The markings are performed with the patient wearing his or her undergarments to help ensure that the incision lies outside of the visible skin and to ascertain any hip asymmetries. Practically speaking, abdominal contour surgery may be termed "torso contour surgery," because the flanks and back rolls are also often treated at the patient's request. Whereas physicians refer to these units as part of the torso, patients express their concerns for these units in terms of the "abdomen." The flank is routinely liposuctioned with an abdominoplasty, or if laxity is present, the incision is extended to a 270-degree lift including the abdominoplasty and flankplasty.

Continued on page 48

The lower incision is first marked by the "lift and drop" method, in which the pannus is initially lifted, the lower incision is marked below the undergarment line between the regions of the anterior superior iliac spines (ASIS), and the pannus is then dropped. For the outer markings, the patient sits in a chair and bends forward at the waist. A dot is placed at the end of each skin crease, and the bottom incision is made from this point laterally to approximately 5-8 cm above the midline vulvar crease. To determine the extent of skin which can be safely resected without placing undue tension on the flap (as well as to ensure that a sufficient amount of lax tissue is excised), the Matarasso Maneuver is then performed. In this maneuver, the patient is placed in a "Miami beach chair" position with a bend at the waist (**Figure 1**). The surgeon then grasps the lax tissue which forms between the lower incision marking and the thumb with gentle downward traction on the abdominal skin. The upper extent of the elliptical incision is then marked at this level. Careful attention to this upper marking technique will facilitate a safe pre-excision of the pannus at the time of surgery, which will greatly increase time-efficiency.

Figure 1 – The Matarasso maneuver. *To determine the extent of skin which can be safely resected the Matarasso Maneuver is performed. The patient is placed with a bend at the waist and the surgeon grasps the lax tissue which forms between the lower incision marking.*

All markings are later verified intraoperatively with criss-cross (overlapping) sutures, a technique pioneered for breast surgery by Brazilian plastic surgeon, Ivo Pitanguy. These markings are performed after the liposuction portion is complete (described below). A long silk suture is secured to the midline xiphoid region, and a second silk suture is placed in the midline at the pubis (**Figure 2**). The sutures are clamped together with a hemostat at varying lengths and moved side-to-side to confirm the symmetry of the elliptical pannus prior to excision.

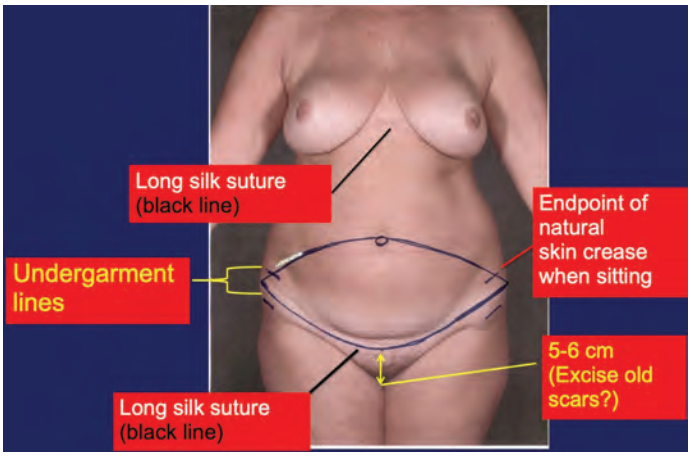

Figure 2 – Pre-operative and Intra-operative markings. *Care is taken to place the lower incision below the patient's undergarment line. The endpoint of the natural skin crease when sitting is marked. The lower incision is placed approximately 5-6 cm above the vaginal introitus and, if possible, prior scars are incorporated into the tissue to be excised. Intra-operatively, criss-cross (overlapping) sutures are used to verify symmetry of the ellipse. A long silk suture is secured to the midline xiphoid region, and a second silk suture is placed in the midline at the pubis. The sutures are clamped together with a hemostat at varying lengths and moved side-to-side to confirm the symmetry prior to excision.*

LIPOSUCTION AND PRE-EXCISION OF THE PANNUS

Once the markings are confirmed, liposuction is performed to the upper flap, mons pubis and flanks, in accordance to the safe zones previously outlined by the senior author (**Figure 3**). One should keep in mind that liposuction influences flap ischemia and thus adhere to safe, proven techniques to avoid an undesirable result. Concomitant liposuction, undermining, and tension are the three key factors that can contribute to flap ischemia. Liposuction is performed prior to the skin incision and undermining to avoid open vascular channels and the potential risk of fat embolism. The surgeon's gloves are changed after the liposuction is completed.

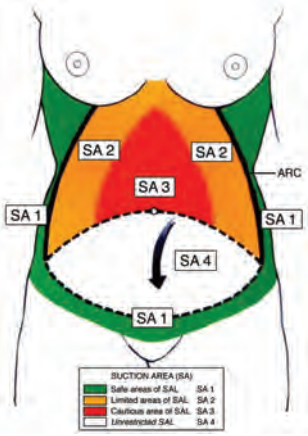

Figure 3 - Matarasso Safe Zones for Liposuction with Abdominoplasty *– Concomitant liposuction contributes to flap ischemia. Adherence to the Matarasso suction area (SA) zones (SA 1 (safe), SA 2 (limited), SA 3 (cautious), and SA 4 (unrestricted)) will help one avoid this undesirable result.*

Pre-excision of the pannus with an initial incision at the upper portion of the elliptical skin pattern is a critical component of a time-efficient abdominoplasty. Maximizing the use of the elliptical incision was promoted by the

late Dr. Jaime Planas of Barcelona, Spain. The pre-excision can be done safely without the removal of excessive tissue with the incorporation of precise pre-operative and intra-operative markings as described above. We have noted several other benefits of pre-excision including preservation of blood and heat, as well as facilitation of inverted "V" flap undermining. Care is taken to maintain a broad intact subcostal perforator blood supply.

After completing the undermining of the abdominal flap in the inverted 'V' pattern, attention is then turned towards correction of rectus diastasis. Plication is performed in a cranial-to-caudal direction beginning at the level of the xyphoid in a two-layer manner. The first layer is a continuously-run imbrication using an O-looped nylon (Ethicon™) as described by Atlanta-based plastic surgeons Nahai and Eaves. This technique evolved from their early attempts to perfect endoscopic abdominoplasties. A looped-suture obviates the need to place a knot at the beginning of this buried, continuous imbrication of the rectus fascia. The suture is continued down to the level of the umbilicus and another, separate looped Nylon is run infra-umbilically from the caudal portion of the rectus diastasis cranially to the umbilicus.

Next, a second layer of plication sutures are placed in order to reinforce the primary diastasis repair. This is performed using a 2-O Neurolon suture in interrupted, buried-of-eight fashion throughout the length of the diastasis. These sutures also help to smooth any midline contour irregularities as a result of the primary plication suture. No sutures are placed running parallel to the midline. Finally, an eye conformer is sutured onto the umbilicus with the outer/convex side facing the umbilical skin. This facilitates easy identification and retrieval of the umbilicus (**Figure 4a and 4b**).

Figure 4-a

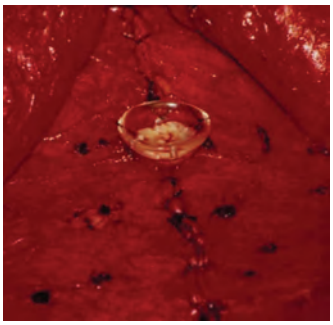

Figure 4-b

***Figure 4 – Umbilical marking and retrieval**. An eye conformer is sutured onto the umbilicus with the outer/convex side facing the umbilical skin (a). The rectus fascia has been repaired. This facilitates easy identification and exteriorization of the umbilicus at the time of closure (b).*

Prior to closure, a final layer of sutures is placed at the waistline at the level of the umbilicus in a cranio-to-caudal orientation. Again, using a 2-O Neurolon suture in interrupted, buried-of-eight fashion, any excess vertical laxity of the waistline at the level of the umbilicus resulting from the supra- and infra-umbilical plications is addressed as described by Ian Monroe.

A reliable pain management method incorporates the use of liposomal bupivacaine. Thirty (30) mL of 1.3% Exparel and 30 mL of 0.25% Bupivicaine with 1:200,000 epinephrine is diluted with 80 mL of sterile normal saline for a final volume of 140 mL. Using a 22-gauge needle on a 10-mL syringe, the liposomal bupivicaine suspension is injected in a sub-fascial plane in an abdominal field block fashion.

The incision is closed in 2 layers, with the deep layer including Scarpa's fascia closed with a 0 or 2-O PDO device run in a bidirectional fashion. The deep dermis is similarly run with a 3-O Monoderm suture. We use the bidirectionally-barbed Quill Knotless Tissue-Closure Device (Angiotech Pharmaceuticals, Inc, Vancouver, British Columbia, Canada), the most common barbed suture, with considerable success in numerous aesthetic procedures. It is the senior author's experience that completion of one or two cases with this technology is sufficient to achieve competency in the closure technique.

Pre- and post-operative photos using the senior surgeon's standard approach are presented in **Figure 5**.

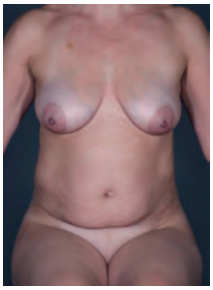

Figure 5-a

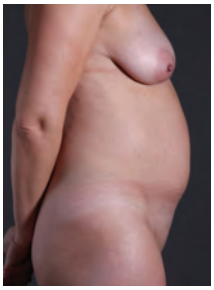

Figure 5-b

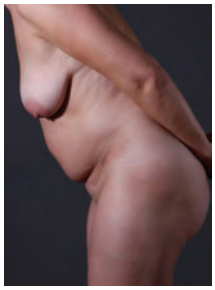

Figure 5-c

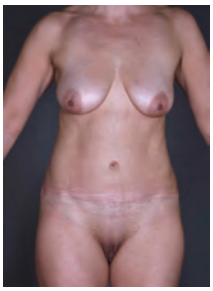

Figure 5-d

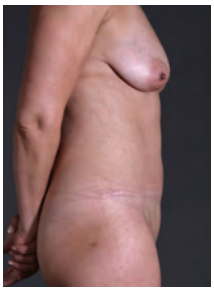

Figure 5-e

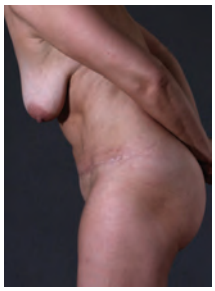

Figure 5-f

***Figure 5 a-c - Pre-operative and d-f - post-operative photos of a lipoabdominoplasty patient**. This procedure was performed using the senior surgeon's standard approach outlined herein.*

Continued on page 50

In **Figure 6**, we present pre- and post-operative photos of a 270-degree extended lipoabdominoplasty, which is used to address excess lateral laxity. This incorporates both an abdominoplasty and a flankplasty.

POSTOPERATIVE MANAGEMENT

Early ambulation on the day of surgery is encouraged, as well as administration of mechanical or pharmacologic anti-coagulation therapy based on the Caprini score and venous thromboembolism risk stratification. Caprini's work has sensitized us to the importance of deep venous thrombosis prophylaxis. A multi-modal pain control regimen allows for earlier ambulation. One part of this therapy is the use of Exaparel. Compression garment use is started at post-operative day two to four, as promoted by Miami-based plastic surgeon Onelio Garcia Jr. Per his work, abdominal compression binders may be associated with increased intra-abdominal compartment pressures which may lead to deep venous thrombosis.

CONCLUSION

Abdominoplasties increasing popularity demand the need to develop a safe, reproducible and time-efficient approach to abdominoplasty is important for today's plastic surgeon. We describe our technique of abdominoplasty and lipoabdominoplasties and refinements that have contributed to our technique.

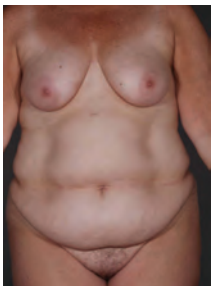

Figure 6-a

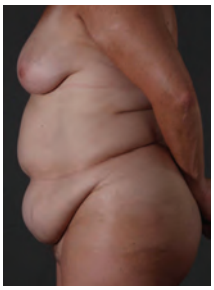

Figure 6-b

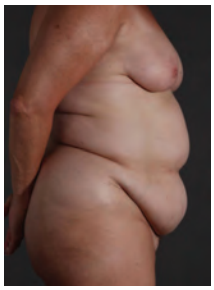

Figure 6-c

Figure 6-d

Figure 6-e

Figure 6-f

Figure 6 - a-c) Pre-operative and d-f) post-operative photos of a 270-degree extended lipoabdominoplasty. *This technique is used to address excess lateral laxity. This incorporates both an abdominoplasty and a flankplasty.*

HD LIPOABDOMINOPLASTY

MARKING AND TECHNIQUE

CAIO PUNDEK GARCIA, MD - BRAZIL

INTRODUCTION

The addition of lipoplasty into the surgical arsenal by Illouz has brought many changes to abdominoplasty procedures. Osvaldo Saldanha popularized unrestricted abdominal liposuction, with limited supraumbilical dissections and scarpa fascia preservation. In liposuction techniques, Henry Mentz and Alfredo Hoyos described the selective fat removal to recreate a muscle appearance and called their techniques physical conditioning and high-definition liposculpture.

METHODS

MARKING:

Marking is performed in an upright position. Patient is asked to contract their abdomen, making it easier to mark abdominal structures and evaluate for possible hernias and diastasis.

The anatomical structures to be reinforced while marking are the linea alba and linea semilunaris. In linea semilunaris, that point touching the costal grid, should be marked, as a more superficial liposuction will be performed on this site to create a local fat depression.

The flank area is the liposuction site. Authors use topographic marking to show sites with the greatest projection and the presence of subcutaneous tissue. (Figure 1)

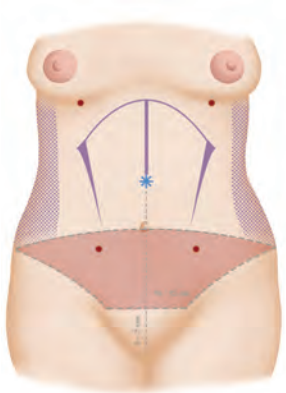

Figure 1 - preoperative marking.

For abdominoplasty, the incision line is placed 5-7 cm from the vaginal introitus. At this point, a 10-14cm horizontal line is marked over the midline, taking the inguinal cutaneous flap as a symmetry parameter. The incision size should extend, at least, up to the limit of the lateral flap of the skin and fat apron. The lateral incision extension should not be limited, as scar asymmetries are due to the need of extending the incision trans-operatively. The surgeon should ensure the incision is made under the anterior-superior iliac crest, so underwear/bikini can hide the scar.

The probable region of the new navel should be marked over the abdominal cutaneous flap. Keep in mind that the midline liposuction marking should only be placed over the new navel position. (Figure 2)

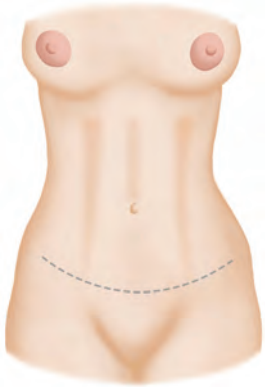

Figure 2 - postoperative projection.

SURGICAL TECHNIQUE:

The procedure starts with liposuction. A superwet saline solution combined with adrenaline (1:500,000) is used. It is important to start the liposuction on the deep fat layer and then proceed with the surface layer. Authors use technologies associated with liposuction, with an aspirator (miniTurbo Coelho®) and

Continued on page 52

many times with the assistance of vibration equipment (Vibrofit Faga®). Five-hole Mercedes standard cannulas of 3.0mm and 3.5mm in diameter are used.

Five incision sites are used to introduce the cannulas: 2 sites on the abdominal dermofat flap, to be surgically removed later, 1 site on the navel area, and 2 sites on the inframammary fold.

In the lateral/flank area, more aggressive liposuction is performed, while on the upper abdominal area slight liposuction is performed, thus making it easier to subsequently create the upper abdominal area tunnel by using electrical cautery through previous dissection by cannulas.

Liposuction is performed over the linea semilunaris area both at deep and superficial levels, in an attempt to mark it through direct view, thus creating a more athletic appearance for the patient. The midline should undergo liposuction at surface level, to create the linea alba draw.

Abdominoplasty is started when liposuction is over. A classic abdominoplasty with the umbilical stump resection for a subsequent neophalloplasty is performed. A dermal cutaneous tunnel is created in a narrow upper abdomen (maximum of 7cm in diameter). If a diastasis in the rectus abdominis muscles is present, their plication is performed by using double-stranded 0-nylon. For this, Baroudi stitches using Vicryl 3.0 over the midline are used.

Authors choose to conduct neophalloplasty as a routine. The preferred technique is the X-shape, with arms measuring 1 cm. Nylon 2.0 is used for flap fixation, and the right upper lateral flap is fixed into the rectus abdominis aponeurosis at a higher position. The left lower lateral flap is fixed into the rectus abdominis aponeurosis at a lower position.

Figure 3 – immediate post-operative novel result.

The position of the new navel is evaluated according to each patient's anatomy. The preferred area ranges from the 1/2 and the 1/3 division lines of the abdomen. For young patients who have an athletic shape, placing the navel at a higher position is allowed. The navel is never placed at less than 7 cm from the lower edge of the flap. (Figures 3 and 4)

Figure 4 – pre- and post-procedure pictures of a 35-year old female with three months evolution.

A Portovac 3.2 suction drain is used, and when drainage is lower than 50 ml/24 h, it is removed.

CONCLUSION

The current trend is to associate abdominoplasty with liposuction to improve reproducibility and produce aesthetically-pleasant results. Additionally, there is acceptable evidence on the safety of the association of these procedures.

REFERENCE

Garcia CP, Mattiello CM, Rendon NB, Zanol F, Vasconcellos ZAA, Ely JB. Lipoabdominoplastia HD: Marcação e técnica. Rev. Bras. Cir. Plást.2019;34(0):128-131

This article is a summary of one published in the Brazilian Journal of Plastic Surgery. Reprinted by permission of the Brazilian Journal of Plastic Surgery.

The author has no financial interest in any company or product mentioned in this article.

HOW I PERFORM ABDOMINOPLASTY

NO DRAINS, NO SEROMAS

ELIZABETH J HALL-FINDLAY, MD, FRCSC - CANADA

I use a standard abdominoplasty (elevating up to the rib margin bilaterally) with quilting sutures and no drains. In my last 633 abdominoplasties, I have had to aspirate one small (30cc) seroma.

Before 2004, I used a standard abdominoplasty with drains and I was not happy with my seroma rate. Most of my patients live at least 100km away, so there is no question that I pulled the drains too early, but making them come back for aspirations was not good for patient management.

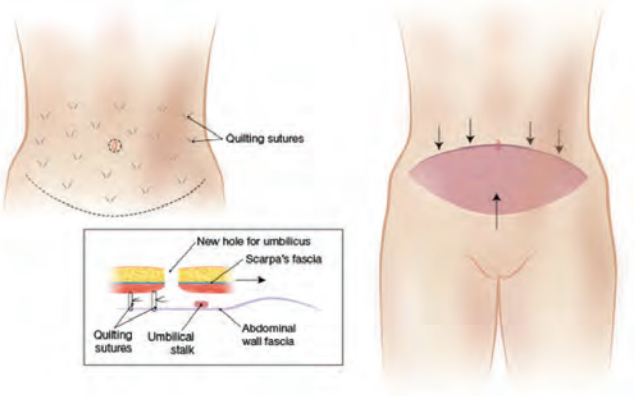

Figure 1 - Quilting sutures with progressive tension advancement modification.

I reviewed 128 patients on whom I performed an abdominoplasty before 2004. I had an abysmal 25% seroma rate and I knew that I needed to change what I was doing. So, I started using quilting sutures (3-0) PDS and my seromas stopped[1-3]. I was still using drains and did so for the next three years when I performed 105 abdominoplasties and had only two seromas. I was only using about twenty quilting sutures per patient and then I increased the number of quilting sutures and stopped using drains.

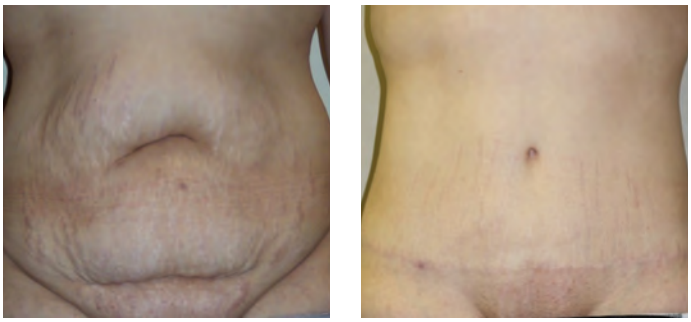

Figure 2 – 5-year follow-up on a 38-year old woman with removal of 2033 gm and 300 cc of liposuction. Patient had had one vaginal delivery and one C-section. She was 80kg and 165cm.

I have not used a drain since the beginning of 2007. As I increased the number of quilting sutures (especially inferiorly), I started noticing that patients had far less swelling above the lower abdominal scar. I have performed over 600 full abdominoplasties in the last twelve years with only one small seroma. I did have four hematomas, but I was fully anticoagulating all my patients at that time. Now I only anticoagulate patients with a Caprini score over seven.

Continued on page 54

Figure 3 - 13-month follow-up on a 32-year old woman to show effectiveness of absorbable sutures in repairing a rectus diastasis. Patient was 45kg and 160cm. She had one vaginal delivery and two C-sections.

I do not perform liposuction on the abdominal flap, but I do contour the lateral hip roll area and the mons if needed.

I do not believe that we need to preserve lymphatics to prevent seroma formation[4]. My complete dissection is just above the fascia. I actually believe that it is important to remove all fat over the fascia where the plication is to be performed because fat does not heal to fat.

I believe that friction causes seroma formation. The quilting sutures prevent the abdominal flap from sliding over the abdominal fascia. I also believe that one of the problems with the Biocell textured implants was that they did not adhere well and the resultant friction caused late seromas and double capsules.

Not only do the quilting sutures prevent friction and seroma formation, but the extra quilting sutures help reduce postoperative swelling. I do not use compression because the quilting sutures act as a form of internal compression. I believe that this also reduces the incidence of DVT because compression garments often prevent venous return.

I use absorbable sutures for fascial plication[5], with one row of interrupted #1 Maxon (easier to tie than PDS) and a second row of running Maxon above and below the umbilicus. When I see patients in consultation, I insist that they have a relatively scaphoid abdomen (heavier patients may need a "lipoabdominoplasty"[6] but I prefer to operate on patients who do not have too much intra-abdominal fat). I tell patients that it is much like having too many clothes inside a soft-sided suitcase. If I try to do up the zipper on a suitcase with too many clothes in it, the zipper will rip; if I try to do a fascial plication with too much intra-abdominal fat, the results will be compromised. The photos below are at one year postoperatively showing how successful absorbable sutures are with fascial plication.

I have tried many different methods for the umbilicus and I have found that the best technique is to cut out a triangle of skin at the 6 o'clock position on the umbilicus and then insert an inverted "V" from the skin flap into the centre of the umbilicus. It is important to de-fat the abdominal flap so that the scars are hidden.

Of course, I have become faster at performing the quilting sutures and I now use a combination of barbed sutures (Statafix) and interrupted 3-O PDS. Most of my abdominoplasties are performed with less than two hours of surgical time.

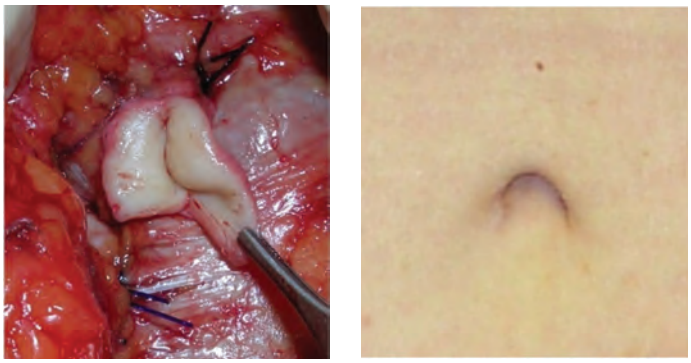

Figure 4 - Umbilical management with removal of a wedge of skin at 6 o'clock and insertion of inverted V from abdominal flap.

For the last few years, we have been performing transversus abdominus plane (TAP) blocks. I learned how to do them after watching a video on YouTube and we use bupivacaine with ultrasound control. Once the anaesthetist has the tube secured, I bring in the ultrasound machine and I do one side. The anaesthetist then does the other side and they have noticed a significant reduction in narcotic use intraoperatively and I have noticed a significant reduction in narcotic use postoperatively. Patients go to the recovery room with minimal pain and minimal nausea. Preoperative TAP blocks work better than intraoperative TAP blocks. The blocks usually take us less than five minutes to perform.

I am now content with my standard abdominoplasty technique using quilting sutures with no drains, no seromas, minimal swelling and a good recovery.

REFERENCES:

1. Baroudi R, Ferreira CA. Seroma: How to Avoid it and how to treat it. Aesthet Surg J 1998:18. 439-441.
2. Nahas FX, Ferreira LM, Ghelfond C. Does Quilting Suture Prevent Seroma in Abdominoplasty? Plast Reconstr Surg. 119(3):1060-1064, March 2007.
3. Pollock TA, Pollock H. Progressive Tension Sutures in Abdominoplasty: A Review of 597 Consecutive Cases. Aesthet Surg J, 2012
4. Tourani, SS, Taylor GI, Ashton MW. Scarpa Fascia Preservation in Abdominoplasty: Does It Preserve the Lymphatics? Plast Reconstr Surg. 136(2):258-262, August 2015.
5. Nahas, FX; Augusto SM, Ghelfond C. Nylon versus Polydioxanone in the Correction of Rectus Diastasis. Plast Reconstr Surg. 107(3):700-706, March 2001.
6. Saldanha OR, Federico R, Daher PF. Lipoabdominoplasty. Plast Reconstr Surg. 124(3):934-942, September 2009.

IS POST LIPOSUCTION ABDOMINOPLASTY SAFE?

HOW TO DECREASE TENSION AND AVOID THE RISE OF THE SCAR BACKGROUND

JESÚS HERRERA PACHECO, MD - MEXICO

Abdominoplasty is one of the most commonly performed plastic surgery interventions. It is the procedure of choice to correct abdominal flaccidity, supra and infra-umbilical lipodystrophy and diastasis of the rectus abdominis.

As we know from the International Society of Aesthetic Plastic Surgery (ISAPS) annual Global Aesthetic Survey for procedures completed in 2018, abdominoplasty is in fourth place among the most popular surgeries and liposuction is in second place.

We are currently facing a big issue: the invasion of our specialty. Every day more liposuctions are performed by non-plastic surgeons and the majority of them are incorrectly indicated. (Figures 1 & 2)

Figures 1 & 2 – The challenges in post-liposuction patients: fibrosis in the abdominal wall, poor circulation.

It is recognized that patients undergoing abdominoplasty with a previous liposuction are at an increased risk for abdominal wall necrosis, and impaired wound healing because of compromised blood supply.

We have seen the need to measure the conventional tummy tuck technique and perform a fixation of the upper abdominal flap. This modification of the technique allows us a better descent of the superior flap, as well as diminishing the possibility of complications such as dehiscence, elevation of the wound and infections.

PATIENTS AND METHODS

We performed 207 abdominoplasties in 6 years in patients between 25 and 60 years old; 130 had previous incorrectly indicated liposuction.

SURGICAL TECHNIQUE

Marking was performed with the patient in the upright position, including the vertical midline reference, the pubic reference line, iliac crest, resection markings, mapped out before incision. (Figures 3 & 4)

Liposuction was performed (not in the superior flap) using cross-hatching with 3- to 4-mm cannulas.

The incision is made to the abdominal fascia and starts detachment with electrocautery to reach the supra-umbilical region; then the dissection is performed at the level of

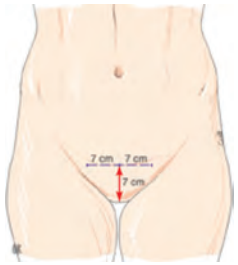

Figures 3 & 4 – Marking

Figure 5 – The dissection only is performed at the level of external edge of both rectus muscles.

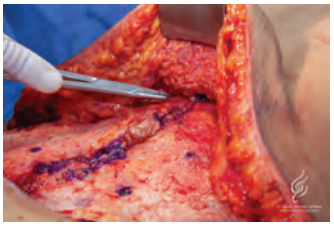

Figure 6 – Progressive tension points are placed using vicryl 2-0.

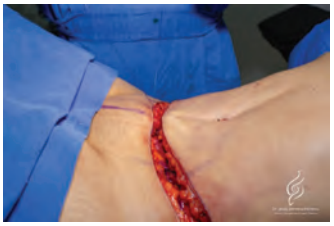

Figure 7 – Fixation of the flap with monocryl 2-0.

external edge of both rectus muscles (Figure 5), the table is positioned in flex and flaps are browsed, resecting the excess skin of superior flap, plication of the recti is done in a conventional manner, progressive tension points are placed using vicryl 2-O until reaching the lower edge (Figure 6), then we carry out a mark with gentian violet in the abdominal fascia, and we start to fix the superior border to the fascia; a point is placed every 2 cm covering deep dermis, subcutaneous cellular tissue, and aponeurotic fascia to face both flaps, using monocryl 2-O. (Figure 7) When fixing the point to the abdominal fascia we decrease tension and avoid the ascent of the flap and therefore the rise of the scar. Subsequently, suture is made with a continuous using 3-O vicryl and the skin is closed with monocryl 3-O intradermal. (Figure 8)

A single, closed, 7-mm drenovac drain is placed and sutured through the incision wound and left until drainage output is less than 50 ml in 24 hours.

Dehiscence of the wound was present in 15 patients, 5 of which required a new closure and the rest heal spontaneously.

We consider that the fixation of the abdominal flap superior to the fascia and the inferior flap diminishes the tension as well as providing lower possibility of dehiscence and the location of the scar post-tummy tuck lower in cases of post-liposuction patients. (Figures 9 - 16)

Figure 8 – Final result.

CONCLUSIONS

We consider that this modification to the surgical technique is very useful in patients with previous liposuction since the fixation of the superior flap procedure resulted in fewer adverse outcomes in patients with previous liposuction. Its use should be considered in patients with significant abdominal fibrosis, It is also very useful in patients who request a traditional tummy tuck.

How did liposuction influence my surgical technique?

Unfortunately, we face a significant number of patients who undergo liposuctions when they need a tummy tuck, so when they come to us, we have to perform a tummy tuck to be able to offer a good result

Over time, we face adverse situations such as wound dehiscence and healing problems. Consequently, we modified the technique to obtain better results, both in post-liposuction patients as well as patients with conventional tummy tuck.

Figures 9 & 10 – 47 year-old female with previous liposuction 2 years before.

Figures 11 & 12 – 54 year-old patient with 3 previous liposuctions.

Figures 12, 13 & 14 – 57 year-old female with liposuction with local anaesthesia.

Figures 15 & 16 – 36 year-old patient with 2 previous liposuctions.

ABDOMINOPLASTY WITH CONCURRENT CIRCUMFERENTIAL BODY LIPOSUCTION

VASILEIOS VASILAKIS, MD – UNITED STATES

JOSEPH P. HUNSTAD, MD, FACS – UNITED STATES

INTRODUCTION

Abdominoplasty and liposuction remain two of the five most common aesthetic surgical procedures performed worldwide. In 2018, it was reported that 1,732,620 liposuction surgeries and 888,712 abdominoplasty procedures were performed, constituting a 9.2% and 9.7% increase since 2017, respectively.[1] The combination of abdominoplasty and circumferential liposuction is performed to concurrently treat abdominal skin excess and abdominal myofascial laxity, as well as adiposity of the flanks, hips, waist and back.

The infiltration of large volume of tumescent fluid containing adrenaline via small-diameter cannulae to achieve a tumesced or turgid state is the key step of the procedure. It achieves vascular preservation via the following properties:[2]

1. Compression of arteries and veins from the fluid pressure allows for easier passage of the cannula and renders the vessels resistant to mechanical trauma.
2. Exsanguination of the microvasculature of the skin flap prevents blood stagnation, release of thrombogenic mediators and microthrombi formation.
3. Minimization of intraoperative blood loss allows optimal and rapid physiologic tissue reperfusion post-operatively.

Lastly, large volume tumescence magnifies the contour deformities and reduces the risk of under- or overcorrection.

MARKINGS – KEY POINTS

The abdominoplasty incision is placed low, to be concealed by the patient's undergarment or swimwear. The patient lifts the panniculus strongly upward, and the level of the pubic symphysis is marked under tension.

- The incision typically extends to the level of the anterior superior iliac spine. The length is determined by the degree of skin laxity.
- Commitment to the upper incision does not take place until the myofascial plication is completed. Any pre-operative markings only act as guidance.
- Topographic liposuction markings are performed pre-operatively with the patient standing. Circular markings indicate the areas to be treated with liposuction whereas hash marks indicate the zones of adherence that are to be avoided. The following areas warrant assessment for degree of lipodystrophy: lateral abdomen (flanks), mons and lateral breast rolls, anteriorly; hips, waist, lower back and upper back, posteriorly.

INTRAOPERATIVE PROCEDURE – KEY POINTS

The execution of abdominoplasty and concurrent circumferential liposuction was first described in detail by the senior surgeon (J.P.H.) in 2011,[2] and it has stood the test of time. Our technique

has since incorporated key advancements, which along with some of the important steps, are outlined here:

- The procedure begins with tumescent infiltration of the entire abdomen and flanks and then the patient is turned prone to complete the liposuction of the posterior areas, before the patient is finally turned supine for the abdominoplasty. This allows the adrenaline in the tumescent fluid to be maximally effective.
- The Separation, Aspiration, and Fat Equalization liposuction (SAFELipo) technique has become our standard technique, to maximize vascular preservation and skin retraction, enhance contour and shape, and minimize injury to adjacent tissue.[3,4]
- Currently, our preference is to utilize ultrasound-assisted liposuction (VASER; Solta Medical, Inc., Hayward, Calif.) as an adjunct to SAFELipo. Energy-based technology to the abdominal flap is not recommended in order to avoid vascular compromise.
- Circumferential liposuction for optimal thickness reduction and skin retraction is performed. Anteriorly, both the superficial and deep layers of fat are treated with liposuction. SAFELipo in conjunction with high volume tumescent infiltration help facilitate this.
- Sub-Scarpa's fat resection eliminates the deep layer, which in conjunction with the elimination of tissue via liposuction, reduce the vascular burden and enhance skin flap reperfusion.
- Our skin flap dissection is aggressive and extends to the costal margins to allow for wide rectus abdominis plication. However, the lipo-abdominoplasty technique that preserves the superolateral perforators is an excellent and safe alternative.[5]
- Wide rectus abdominal plication (WRAP) is performed using a looped double-stranded number O nylon suture in running fashion. It dramatically shortens the umbilical stalk and eliminates the need for tacking or other umbilical sutures.
- A 7 mm Jackson-Pratt drain is used to drain the lower back and is brought out through the proposed skin excision pattern anteriorly. A similar drain is used to drain the abdominoplasty site.

POSTOPERATIVE CARE – KEY POINTS

- Aggressive hydration – ideally via intravenous (IV) fluids overnight – for seventy-two hours post-operatively, to overcome the sympathetic vasoconstriction.
- Minimize tension by maintaining flexed position for up to ten days.
- Maximize comfort with the use of a garment, appropriately fit to prevent skin folds.
- Frequent assessment for signs of dehydration (and the need for IV fluid administration), garment application and skin wrinkles, skin or deep infection, ischemia, incisional compromise, hematoma and seroma is paramount.

CONCLUSIONS

Abdominoplasty with concurrent circumferential liposuction is a comprehensive and safe body contouring technique that achieves superior enhancement of shape and contour. The most important element of this technique is the infiltration of large volume tumescent fluid until turgid state is achieved circumferentially, which optimizes vascular preservation.

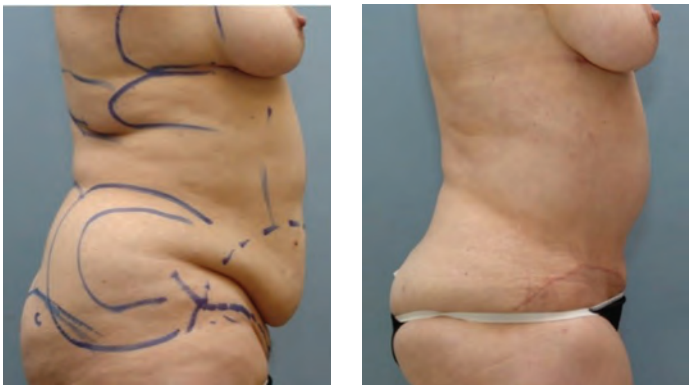

Figure 1. Pre-operative (A) and six-month post-operative (B) photographs of a 49-year-old female patient who underwent abdominoplasty with wide rectus abdominal plication and concurrent circumferential body liposuction. The total volume aspirated was 11,375 ml, of which 6,595 ml was pure fat.

REFERENCES

1. International Society of Aesthetic Plastic Surgery. 2018 ISAPS International Survey on aesthetic/cosmetic procedures. Available at: https://www.isaps.org/wp-content/uploads/2019/12/ISAPS-Global-Survey-Results-2018-new.pdf. Accessed December 23, 2019.
2. Hunstad JP, Jones SR. Abdominoplasty with thorough concurrent circumferential abdominal tumescent liposuction. *Aesthet Surg J*. 2011;31(5):572-90.
3. Wall S Jr. SAFE circumferential liposuction with abdominoplasty. *Clin Plast Surg*. 2010;37(3):485-501.
4. Wall SH Jr, Lee MR. Separation, Aspiration, and Fat Equalization: SAFE Liposuction Concepts for Comprehensive Body Contouring. *Plast Reconstr Surg*. 2016;138(6):1192-1201.
5. Sozer SO, Basaran K, Alim H. Abdominoplasty with Circumferential Liposuction: A Review of 1000 Consecutive Cases. *Plast Reconstr Surg*. 2018;142(4):891-901.

The authors declare that they have no conflicts of interest to disclose. Informed written consent as permission for the use of the patient images was obtained. No acknowledgments.

ABDOMINOPLASTY: AVOIDING PITFALLS

SANDIP JAIN, MCH, FRCS – INDIA

Pitfalls if not recognized and mitigated during planning and execution of abdominoplasty can mar the final aesthetic outcomes.

Most common is misjudging the extent of skin laxity. For instance, the earliest sign of supraumbilical laxity may be horizontal orientation of umbilicus and only later a concertina effect on the skin is apparent. In such situations, performing a mini-abdominoplasty instead of standard abdominoplasty would give suboptimal results. In Figure 1, the left side

Figure 1 - Left side shows mini - abdominoplasty result. On the right after converting to standard abdominoplasty.

shows the result of mini-abdominoplasty performed in a patient with supra-umbilical laxity. Result after standard abdominoplasty is shown in Figure 1 on the right side. Similarly, performing standard abdominoplasty in patients with circumferential laxity would mar the aesthetic result, as evident in Figure 2 left side. Positive translation test (pinching the flanks corrects the lateral thigh laxity) and signs of buttock ptosis are tell-tale evidence of circumferential laxity. This patient finally underwent lower body lift resulting in dramatic improvement in the abdomen as well as thigh contour (Figure 2 right side).

Figure 2 - Shows on the left side standard abdominoplasty. On right side after conversion to lower body lift.

Transverse laxity in the upper abdomen can be ascertained by pinching the skin in a horizontal fashion. Figure 3 shows a patient who refused to have the anchor abdominoplasty and only underwent lower body lift. He subsequently was distressed about the residual laxity in the midriff area

Male abdominoplasty patients often have a hidden penis due to overhanging pannus. If not recognized and corrected, this can lead to dissatisfaction. These patients require aggressive defatting and suspension of the mons to reveal the external genitalia - Figure 4. Often there is horizontal excess as well in the mons area. This needs to be shortened by removing vertical ellipse of skin on either side of mons as continuation of medial thighplasty.

The other pitfall is incorrectly "siting" the abdominal scar. Most common situation is either the whole scar is high - Figure 5 - or the lateral end of the scar is lower than the rest of the scar. Asymmetrical scar is also often seen. To prevent the high scar, one should mark the lower incision with the abdominal pannus pulled maximally in the cranial direction. At the level of the mons, it should be 5-7 cm from anterior vulvar commissure. In the inguinal region, it should be not more than 2-3 cm from the inguinal crease. The lateral end of the incision is marked without pulling the pannus in the cranial direction. This way the lateral end of the scar doesn't end up lower than the rest of the scar. Ideal scar location should have lowest point at the midline mons and the highest point at the lateral end. From the mons to the lateral point the scar should be inclined at a gentle 45 degrees.

The best way to mitigate an asymmetrical scar is symmetrical marking. All parts of the marking should be measured from fixed bony landmarks to ensure symmetry. Also, the upper marking is ascertained and confirmed by intraoperative tailor tacking. Once the final marking is made, one should not deviate from it while making the incisions.

Umbilicus re-siting can also be tricky. A common mistake is to ascertain the position of the umbilicus in the superior flap with the patient flexed in a beach chair position. This is more of a problem if the umbilicus has a long stalk. Then as the patient straightens out postoperatively, the umbilicus slowly migrates cranially and ends up as a high umbilicus.

A final pitfall is the development of a keloid scar at the site of umbilicoplasty. Periumbilical scar is the only visible scar in abdominoplasty. If this becomes keloidal, it can cause immense distress to the patient. Therefore, patients who have a keloid tendency (Fitzpatrick Type 4 and above) should have the option to choose scarless umbilicoplasty.[1]

Citation: 1. da Silva Júnior, V.V. & de Sousa, F.R.S. Aesth Plast Surg (2017) 41: 600.

Figure 3 - Transverse laxity shown in the midriff area on the right image despite lower and upper body lift.

Figure 4 - Aggressive defatting and suspension of mons to reveal hidden penis.

Figure 5 - High scar requiring revision abdominoplasty to lower the scar.

RESTORING FORM IN ABDOMINOPLASTY

CHRISTOPHER PATRONELLA, MD – UNITED STATES

As plastic surgeons, we strive to provide ideal aesthetic improvements with minimum surgical stigmata. Today, we are more attentive to subtle anatomical details than ever before, incorporating adjunctive techniques, such as facial fat grafting during facelift surgery, to enhance youthful anatomical features. Traditional abdominoplasty often failed to recreate anatomical nuances such as the soft contour valleys of the linea alba and linea semilunaris, resulting in a uniformly, flat-as-a-board and excessively taut abdomen. Today, the more sophisticated, 21st century consumer has available digital multimedia resources from around the globe and has become keenly informed about the details of the procedures we perform and now often rejects less attractive, unnatural changes.

Our group recognized the attractiveness of a detailed treatment of the abdomen with the publication of our paper, Abdominal Etching: Differential Liposuction to Detail Abdominal Musculature in the *Aesthetic Plastic Surgery Journal* in 1993. In our experience, concomitant liposuction of the abdomen during abdominoplasty increased vascular perfusion complications with the procedure, especially in patients requiring a more comprehensive abdominoplasty for correction of skin redundancy of the upper abdomen. My approach evolved beginning 20 years ago, stimulated by my own dissatisfaction with the uniformly flat and overly tight abdominoplasty that I learned in my training. While most patients didn't complain, many noticed the unnaturalness, so I supplemented with secondary liposuction to enhance anatomical definition. The procedure I perform today is markedly different, incorporating numerous details and requiring an extra 45 minutes, but vastly more satisfying for my patients and me. The two most impactful maneuvers in this abdominoplasty, direct differential sub-Scarpa's fat thinning and Anatomy Defining Progressive Tension Sutures, are combined to create a more authentic, toned abdomen.

In order to fully implement my strategy of comprehensive treatment of the abdominal aesthetic unit, thorough flap mobilization is required, thus making concomitant liposuction a less safe alternative. Full mobilization allows recruitment of upper abdominal skin laxity, which can be conservatively thinned when necessary and advanced. Once the flap is elevated, the vascularity of sub-Scarpa's fat is entirely dependent on the subdermal plexus, and, therefore, sub-Scarpa's fat can be safely resected directly without affecting flap perfusion. Direct sub-Scarpa's fat thinning of the flap is performed, specifically directed over the linea alba and linea semilunaris, as well as over the external oblique fossa. Additionally, less aggressive thinning is performed over the remaining skin flap, resulting in a differential treatment that more closely resembles the youthful, toned abdomen. Pretreatment of the abdominal flap with vasoconstrictive tumescent solution allows more clear identification of tissue planes, and Scarpa's fascia becomes easily recognized as the endpoint of fat resection (Figure 1).

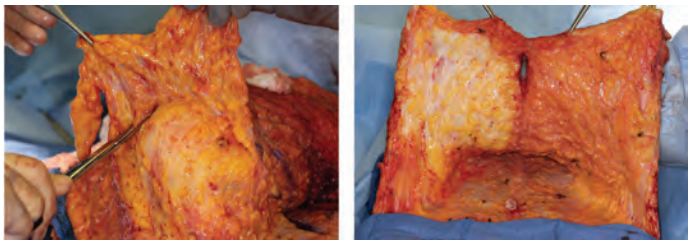

Figure 1- Sub-Scarpa's fat resection.

An anatomy-defining application of progressive tension sutures (PTS) requires placement in a specific pattern aimed to enhance muscular definition (Figure 2). Stabilizing the skin flap with PTS prevents serous fluid collection and bursa formation, preventing a blunting effect along these fascial zones of adherence. Stabilizing the flap with PTS splints the subcutaneous-fascial interface along the linea alba, linea semilunaris and over the external oblique fossa, promoting scar tissue adherence during the healing process (Figure 3). With a properly performed PTS technique, drains are not needed, adding comfort and convenience for patients, and enhancing the surgical experience. Differential fat thinning combined with reestablishing zones of adherence produces lasting abdominal wall definition which becomes more distinct, gradually, over a six-month period following surgery. Long term follow-up with patients undergoing this procedure has consistently demonstrated maintenance of anatomical definition in those who also maintain stable weights (Figure 4).

In summary, a positive patient experience and good outcomes are critical to a high level of patient satisfaction. The techniques I've described are a major component of my overall strategy for enhancing abdominal wall definition during abdominoplasty (1), providing a more authentic-appearing outcome and, as a result, improving patient satisfaction. Other important steps such as detailed treatment of the mons and umbilicus, which are beyond the scope of this review, are covered in the original article with accompanying procedure video in the *Aesthetic Surgery Journal* in November/December 2015 (1).

REFERENCE:

1. Patronella, CK. Redefining Abdominal Anatomy: 10 Key Elements for Restoring Form in Abdominoplasty; Aesthetic Surgery Journal 2015, Vol 35(8) 972–986;

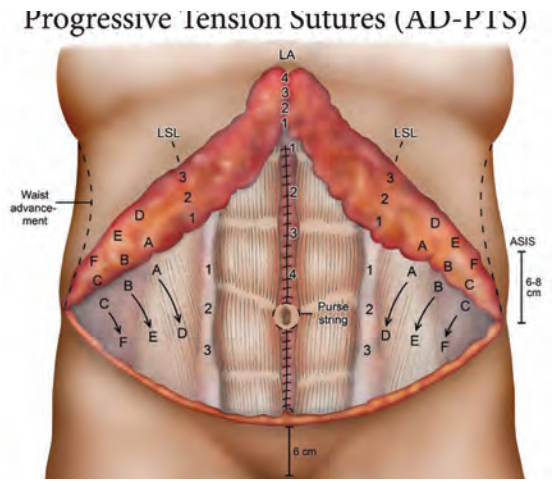

Figure 2- Anatomy Defining Progressive Tension Sutures - linea alba, linea semilunaris and external oblique fossa.

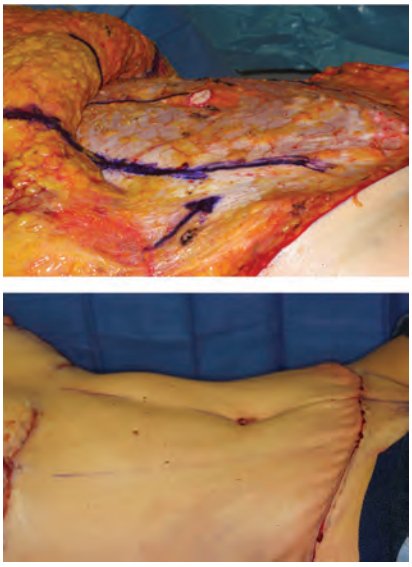

Figure 3- On table profile demonstrating Anatomy Defining Progressive Tension Sutures.

Figure 4 – 3-year post-op

GLOBAL PERSPECTIVES: ABDOMINOPLASTY

BABIS RAMMOS, MD, FACS – UNITED STATES

Abdominoplasty offers improvement in the contour and external appearance of the abdominal wall and contributes to a natural appearance of the umbilicus. The technique selected for abdominoplasty operations depends on the presenting patient deformity. Abdominoplasty has a long history of technique evolution with various reported methods and refinements. These approaches vary from minimally invasive to multiplane dissections. We present our approach to improve abdominal aesthetics.

SURGICAL PROCEDURES

According to the American Society for Aesthetic Plastic Surgery National Data Bank Statistics, approximately 158,000 abdominoplasties were performed in the United States in 2018, making it the 4th most common aesthetic surgical procedure. Redundant skin, adiposity, muscle diastasis, and unsightly scars, are common presenting complaints for patients seeking elective abdominoplasty.

ABDOMINOPLASTY WITH DRAINS AND SYNCHRONOUS LIPOSUCTION

The abdomen is tumesced with dilute Lidocaine and epinephrine through paired inferior abdominal incisions. A 4 mm basket cannula without suction is then used to separate the fat. Power assisted liposuction is then performed until an appropriate volume of fat is removed and confirmed with a pinch test and the contour is smooth. We then begin the abdominoplasty portion of the procedure.

The lower abdominal incision is made sharply. Dissection is carried down to the fascia with cautery. The periumbilical skin is incised, and the stalk is freed to the fascia. Dissection of the abdominoplasty flap is carried superiorly until the xiphoid process and costal margins are reached. A looped O Ethilon is run from the xiphoid to the pubis for a tight muscle plication. Exparel is injected into the anterior rectus fascia and laterally into the obliques. The patient is then placed in the semi-Fowler position. The superior incision site is marked with a demarcator. The tissue is divided and passed off the field. The abdomen is temporarily stapled to simulate closure. The midline is confirmed, a vertically oriented skin ellipse is resected, and the umbilicus exteriorized.

A JP drain is brought through the right groin and secured. The abdomen is closed in layers with PDS in Scarpa's layer, and 3-O Monocryl in the deep dermis and 4-O Monocryl in the subcuticular layer. The umbilicus is inset with a 3-O Monocryl deep dermal layer and running subcuticular 4-O Monocryl. A clinical result of an abdominoplasty with drains and synchronous liposuction is shown (Figure 1a, 1b).

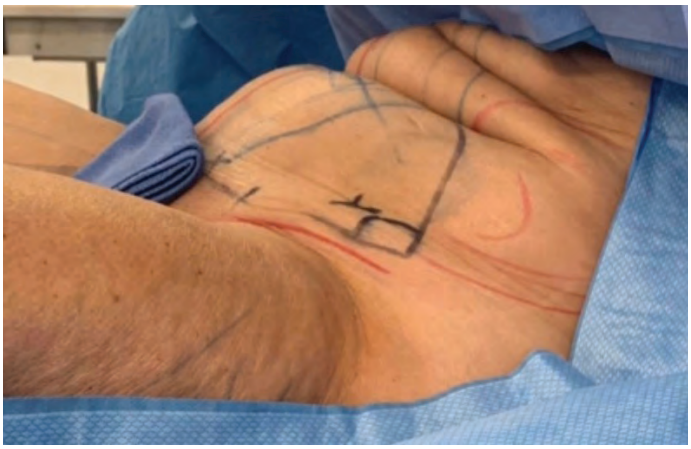

Figure 1a – Intraoperative lateral view of 50-year-old female with abdominal lipodystrophy.

REVERSE ABDOMINOPLASTY WITH DRAINS AND SYNCHRONOUS LIPOSUCTION

The abdomen is tumesced with dilute Lidocaine and epinephrine through paired superior abdominal incisions. Power assisted liposuction is performed until an appropriate amount of fat is removed and the contour is smooth. The inframammary incision is made. Dissection is continued caudad. The anterior rectus sheath is plicated from the pubis to the xiphoid using a looped O Ethilon. The patient is then placed in the semi-Fowler position. The upper abdominal skin flap is demarcated, and the excess skin trimmed.

Figure 1b – Postoperative image obtained at 1-month follow up after abdominoplasty with drains and synchronous liposuction.

FLEUR-DE-LIS ABDOMINOPLASTY

In the preoperative area, an additional proposed vertical excision pattern is marked. The initial part of the procedure proceeds as a traditional abdominoplasty. The corners of the proposed vertical excision are grasped with towel clamps and then crossed over each other with equal tension at the low midline. Towel clamps are used to approximate the vertical resection pattern and then bimanual palpation is used for confirmation. The skin is then incised sharply and the flap margins are divided with cautery. A clinical result of a Fleur-de-Lis abdominoplasty is shown (Figures 2a, 2b).

Figure 2a – Preoperative frontal diving view of a 40-year-old female with vertical and horizontal laxity of the abdomen.

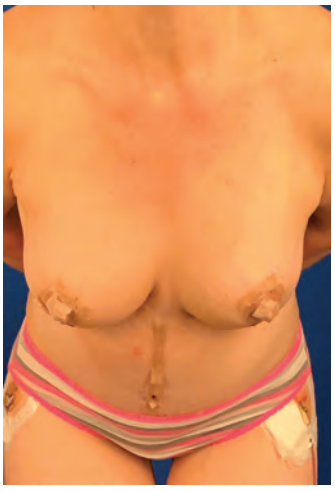

Figure 2b – Postoperative Image obtained at 3 weeks follow-up after Fleur-de-Lis abdominoplasty.

NO DRAIN ABDOMINOPLASTY WITH THE USE OF PROGRESSIVE TENSION SUTURES

By using this technique, drains are not placed. Two double armed 1 Quill PDO sutures are placed as progressive tension sutures, with one placed on each side of the midline. The sutures are placed as an inverted "V", one for each hemiabdomen. This results in elimination of the dead space, and decrease of tension at the wound closure.

In conclusion, there are many well-described surgical approaches to address abdominal wall aesthetics. The ultimate goal is to create beauty and balance while minimizing evidence of intervention.

TWO POSITION APPROACH TO ABDOMINOPLASTY

RENATO SALTZ, MD, FACS – UNITED STATES
ISAPS Past President

MELODY SCHEEFER-VAN BOERUM, MD – UNITED STATES

INTRODUCTION

This article illustrates details of the two-position comprehensive abdominoplasty technique.[1] A total remodeling of the torso is undertaken, in a 360-degree view, with creation of a well-defined and sculpted abdomen with a low, inconspicuous scar, a flat lateral profile, and an hourglass shape of both the abdomen and back. (See Figure 1) The ultimate goal is to provide the aesthetic body contouring surgeon with the tools for an optimal result, fulfilling patient expectations while using safe techniques in abdominoplasty.

PRE-OPERATIVE EVALUATION

Safety issues related to abdominoplasty start during the consultation. A complete history and physical exam are obtained, with special attention to body mass index (BMI) and risk factors for venous thromboembolism. Patients with BMI >29 are counseled to lose weight. The exam includes evaluation for rectus diastasis and hernias.

MARKINGS

The patient is marked in a standing position starting with the upper back, lower back, and flank areas. The abdominal midline is then marked, along with an estimation of excess skin and fat in the lower abdomen. With the patient in a semi-sitting position at the edge of the bed, the lowest abdominal crease, including the lateral extent of the skin fold, is outlined. This will help avoid "dog ears" requiring late revisions. After induction of anesthesia, markings are finalized by placing the lowest portion of the abdominal incision 6 to 7 cm from the anterior vulvar commissure.

SURGICAL SEQUENCE

With the endotracheal tube secured, the patient is carefully proned with padding under the arms, breasts, and hips. The table is flexed and warm tumescent solution is infiltrated. A superior midline incision is placed at the level of the brassiere and an inferior midline incision at the superior portion of the gluteal cleft. Liposuction is completed in all pre-marked areas using the power-assisted liposuction system.

Next, the patient is carefully turned supine, prepped and re-draped. Incision symmetry is verified by triangulation technique, which consists of 2-O silk placed above the xyphoid and above the pubic bone. The first incision is around the umbilicus, using single hooks at 12 and 6 o'clock, and dissection is carried down to the anterior fascia in a perpendicular fashion using a curved scissors, preserving enough periumbilical tissue to maintain blood supply. After

the lower, suprapubic horizontal incision is made, a midline tunnel is undermined all the way above the xiphoid process, preserving lateral rectus perforators.

Next, rectus diastasis is identified and two lines are drawn from the xyphoid to the pubis. A running barbed 1-O PDS suture is used to repair the diastasis. Following fascial injection of Exparel® (bupivacaine liposome injectable suspension), a 2-O PDS running barbed suture is used at the midline between Scarpa fascia of the flap and the anterior rectus sheath, superior to the umbilicus, to decrease dead space, take tension off the midline closure, and to create a midline sulcus. Using pull-down technique with the bed flat, a vertical midline incision is made in the lower abdominal flap, and the suprapubic incision is stapled to the apex of the vertical incision. The bed is then flexed to 30 degrees, and the full lateral extent of abdominal flap to be discarded is determined. When necessary, a vertical midline scar, representing the old umbilical window, is left. Contouring of the flank areas is safely achieved: Scarpa's layer is identified using skin hooks for retraction, then sharp knife or electrocautery dissection under tension is carried out below Scarpa's layer, removing a uniform thick layer of flank and lateral abdominal fat. The intact fascia is protected and maintained with the abdominal flap blood supply in mind.

Before placing an umbilical finder and securing it with Nylon sutures, the umbilicus is first secured to the abdominal fascia. Drains are extended from the suprapubic area to the lower back bilaterally. The abdominal incision is stapled closed, and with the patient in a semi-sitting position, the patient is observed for extra skin or fat in the form of "dog ears." Once any necessary adjustments have been made, Scarpa's fascia is closed with running 2-O PDS barbed suture, following by 3-O Monocryl® interrupted deep dermal and subcuticular running. The second component of the umbilical locator is then applied, determining the position of the umbilicus. An umbilical window is made via a vertical elliptical excision and the umbilicus is set using 2-O PDS at 12 and 6 o'clock. The remaining umbilical closure is secured with interrupted dermal sutures of 4-O Monocryl® followed by Dermabond®. Steri strips are placed on the remainder of the incisions, and final dressings include Topifoam® with a girdle, to be worn for 4 to 6 weeks.

POSTOPERATIVE CARE

Promoting safe surgical practice and prevention of catastrophic events is the surest way to optimize final outcomes. Prevention of venous thromboembolism includes early and aggressive postoperative ambulation and low-molecular-weight heparins (Lovenox®) starting at 8 hours postoperatively (continued for 7 days). Scar massage, lymphatic therapy, and silicone sheets are frequently used. Patients are seen frequently in the early postoperative period, to recognize and mitigate complications quickly. Revisions are addressed at the one-year visit, where it is not uncommon to recommend small improvements. In summary, two position comprehensive abdominoplasty is a powerful and safe body sculpturing tool, which has high patient and surgeon satisfaction.

REFERENCE:

1. Saltz, R. (2014). Two position comprehensive approach to abdominoplasty. Clinics in plastic surgery, 41(4), 681-704.

Figure 1 – A. Frontal view B. Left Oblique C. Right Oblique D. Posterior

SHORT CASE STUDY

HOW TO DEAL WITH A DIFFICULT CASE?

JUAN ESTEBAN SIERRA MEJIA, MD – COLOMBIA
ISAPS Assistant National Secretary for Colombia

Do you know what to do when a surgery accident occurs? Part of the patient's safety in aesthetic surgery is acting right and fast. Prevention is definitely essential; however, unexpected events can come up.

This is the case of a patient in whom I performed an abdominal liposuction and breast augmentation. I requested warm physiological serum to place temporarily on the abdomen in order to increase skin perfusion, while I was performing the breast procedure. Unfortunately, neither the nurse nor her assistant checked its temperature before placing it on the abdomen and when I noticed, there was a large area of her abdomen with erythema. We immediately removed the serum and placed cold water instead, but the erythema persisted.

Figure 1

In these cases, running away is not an option, blaming someone on the team doesn't solve anything, so the only alternative is to continue working proactively, think about possible solutions or face the consequences. In this specific case, the patient suffered a second-degree burn (Figure 1). Although it was difficult to face this situation, I thoroughly explained to the patient and her family what had happened, and the corresponding treatment that would follow. Unfortunately, the patient developed an unsightly scar (Figure 2), but taking responsibility and accompanying her throughout this process was certainly crucial in strengthening the patient-doctor relationship.

At this point I referred the patient to my colleague and friend, who lives in her hometown, in order to make it easier for the patient to consult. He treated her and always and periodically reported the progress to me.

We didn't hear about the patient for a while until she returned with a nice surprise; she was 32-weeks pregnant and the scar looked worse. (Figure 3) I was overjoyed to know about her pregnancy since it gave me a one and only opportunity to fix the scar.

We still didn't know how the skin would be at the end of her pregnancy, but we agreed she would let us know as soon as she delivered the baby, so we could plan the surgery.

A couple of weeks later, as I was checking Instagram, I realized she had already had the baby, so I immediately called her and scheduled the scar resection. When I examined her, I found an unaesthetic, irregular scar, compromising skin and subcutaneous tissue, higher on the right side than on the left. I was especially concerned about the belly button fence and the chances of rebuilding it. (Figure 4)

I considered three options to approach the scar: the first one was to resect the scar and make a primary closure leaving a high and oblique and aesthetic scar; the second one was to pull the upper flap to a lower region of the abdomen, leaving a high scar; and the third one was to stretch the lower flap leaving the new scar as low as possible.

First, we made an incision at the top edge of the scar, and then, we made the upper abdomen dissection in its entirety to the rib edge. After that, we performed the abdominal recti muscle plication and then started making tension and adhesion sutures with Vicryl O in continuous suture in the medium and paramedian line, joining the flap to the muscular abdominal wall. We placed the surgical table in flexion at 40º observing that the flap managed to descend enough to make the lowest resection. We removed the flap with all the scar and continued to descend and perform the plication of the lower abdomen. Then we did a stress test until we managed to pulled the flap as low as possible leaving the scar in the best place.

It was by applying the principles that I used in all my patients throughout these 22 years that I managed to reach such a satisfactory result. (Figure 5) A comprehensive knowledge of both, cosmetic and reconstructive surgery allows us to make better decisions.

The use of "natural skin expanders", when possible, may be the best solution in many cases. Otherwise, the use of synthetic expanders is a viable option. In this case, the unexpected pregnancy was optimal in helping us solving the issue.

Having friends and colleagues who lend us a hand at different times is always a great option. Thanks Jorgen!

Good patient-doctor relationships enable us to manage to accompany them throughout the recovery process and keep their confidence intact until we can think and offer them the best option.

Figure 2

Figure 3

Figure 4

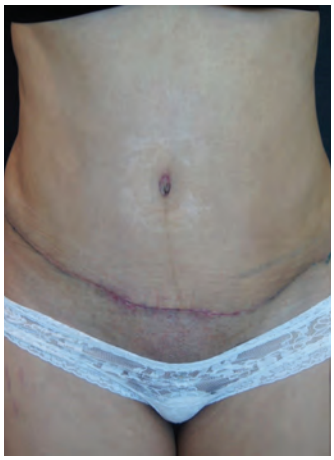

Figure 5

SURGICAL MARKINGS

HOW I MARK: ABDOMINOPLASTY WITH SYNCHRONOUS LIPOSUCTION

BABIS RAMMOS, MD, FACS – UNITED STATES

A thorough physical examination is necessary to evaluate the skin, subcutaneous tissue, underlying recti diastasis and the presence of a hernia.

MARKINGS

The patients are asked to wear their swimwear or undergarment at the day of surgery so that the final incision can be marked in a manner that it is easily concealed. The patient is marked in the upright standing position.

- Patient is asked to pull upwards on the lower skin excess and the lower incision is marked, at the level of the symphysis pubis, approximately 1/3 inferior to the level of the hairline (**Figure 1**).
- A vertical line is drawn from the xiphoid to the commissure. Incision length is determined by the laterality of the patient's skin laxity. The upper incision line marking for the skin resection pattern is only an estimation (**Figure 2**). Markings for liposuction of the flanks, abdominal skin outside of the proposed skin resection area, and mons are also placed.
- Intraoperative, after tumescence infiltration, power assisted liposuction is performed first. The lower abdominal incision is then made sharply. Dissection is carried down to the fascia with cautery. The periumbilical skin is incised sharply, and the stalk is freed sharply to the fascia. Dissection of the abdominoplasty flap is carried superiorly until the xiphoid process and costal margins are reached. A looped O Ethilon is run from the xiphoid to the pubis for a tight muscle plication. The patient is then placed in the semi-Fowler position. The superior incision site is marked with a demarcator. The tissue is divided and passed off the field. The abdomen is temporarily stapled to simulate closure. The midline is confirmed, a vertically oriented skin ellipse is resected, and the umbilicus exteriorized. A JP drain is brought through the right groin and secured. The abdomen is closed in layers and the umbilicus is inset.

Figure 1: The patient is marked in the upright standing position, and the lower incision is marked.

Figure 2: The proposed upper incision is then marked.

MEMBER SPOTLIGHT

GABRIELE CACERES MIOTTO, MD, MED - UNITED STATES
MEMBER SINCE 2009

ISAPS Assistant National Secretary for the United States
Member, Education Council and Communications Committee

How long have you been a member of ISAPS? Why did you join?
I am an ISAPS member since 2009. Dr. Foad Nahai was the ISAPS President at that time and I still keep my original ISAPS member certificate signed by him. It is very special to me, since he later became one of my teachers and now, I am one of his work partners.

I joined ISAPS because I value continuing aesthetic education and networking with international colleagues. I attended the ISAPS Congress in Rio de Janeiro in 2006 when I was still a resident and I loved the meeting. I learned so much. There weren't resident membership options at that time as we have now, so I applied to become a member as soon as I could join as a practicing plastic surgeon.

What is your current role in ISAPS? Where would you like to be five years from now in ISAPS?
Currently, I am one of the ISAPS Assistant National Secretaries for the United States and support our National Secretary in encouraging new applications for membership, as well as serving as a liaison between ISAPS members and the officers of the society. I am also a member of the ISAPS Education Council and the Communications Committee.

In five years, I want to keep serving ISAPS members as a National Secretary and as an active educator at ISAPS Symposia and Congresses. I enjoy teaching aesthetic surgery to residents and fellows in my current position as Assistant Professor in the Division of Plastic Surgery at Emory University in Atlanta. Being fluent in English, Portuguese and able to communicate in Spanish well, has been a positive asset in many aspects of my life and plastic surgery practice. I would love to become an ISAPS travelling professor one day and help spread the ISAPS mission of aesthetic education worldwide, and of course, learn more from our amazing plastic surgery colleagues.

What are your areas of specialty within plastic surgery?
The details of the human face have always fascinated me, and facial surgery was the main reason I chose to be a plastic surgeon. Facial aesthetics is the focus of my practice, and I strive daily to refine my skills in all surgical and non-surgical procedures of the face. I have worked with and visited several amazing plastic surgeons, facial plastic surgeons and oculoplastic surgeons over the years and learned a lot from them. I really enjoy doing facelifts, eyelid surgeries, and facial fat grafting, and have built a strong injectables practice since I do it all myself. I also love aesthetic breast surgery, and mastopexy is my favorite breast procedure.

What else do you do outside of the office?
I enjoy travelling and being in nature, especially at the beach. Being with my family is also very important to me. I am a stepmom of three wonderful kids and love spending time with them and with my husband. I go visit my parents and brother as often as possible in Brazil. I also have a rescue dog and enjoy being his personal groomer.

Continued on page 72

MIOTTO CONTINUED

Exercising my body has always been enjoyable and part of my physical and mental health since childhood. I've been a classic ballerina and ballroom dancer, a competitive swimmer and now I practice yoga since 2005. I recently I started taking pop dance lessons and I am having a lot of fun with it!

Tell us about your current side business with your husband.
My husband is also a plastic surgeon and a tremendous inventor. He has created a few medical devices in the past, and over the last ten years he has been working on a novel non-invasive wound closure and scar treatment device that is finally coming to the market this year. The product is called Brijjit. It is a force modulator tissue bridge that substitutes sutures during skin closure and optimizes scarring by taking tension off the wound edges. He is the company CEO and the engineer brain behind it, and I help with clinical use of the product and support. It is wonderful to see his passion and dedication to it and how much teamwork and resources are required to bring a new medical device to the market.

If you met your husband through plastic surgery, please tell us how.
I did meet my husband through plastic surgery. It was at a plastic surgery meeting in Sao Paulo, Brazil in 2008. I was helping with the meeting organization and he was one of the international guests, but I had never heard of him before. He impressed me with his kindness. At the meeting, some dear friends from Brazil and the USA introduced us and told us (individually!) that we would be a good match. I did not speak English well and he did not speak any Portuguese (my native language). But somehow our friends were right, we took a leap of faith, made a long-distance relationship work for a couple of years, and we have been together for more than a decade. Plastic surgery brought us together and it is special to be married to someone who shares the love for the same profession.

HISTORY

RICCARDO F. MAZZOLA, MD - ITALY
Associate Editor, History of Medicine

PAOLO MASCAGNI (1755-1815)
AUTHOR OF THE MOST BEAUTIFUL ATLAS ON THE LYMPHATIC VESSELS

Paolo Mascagni ranks among the most prominent anatomists of all time (1). He is well known for having discovered the great majority of the lymphatic vessels and for having produced the most beautiful atlas on this topic, a masterpiece of anatomical illustration.

Life - Mascagni was born to a wealthy family in 1755 in Pomarance, near Pisa (Tuscany). He studied in Siena and entered the Siena Medical School, graduating in 1778 in Medicine and Philosophy. Stimulated by his teacher, Pietro Tabarrani (1702-1779), he did detailed research on the lymphatic vessels. The year after Tabarrani's death in 1779, he was appointed a Lecturer in Anatomy at Siena University by the Grand Duke of Tuscany, Leopoldo of Lorena. Many important discoveries in the field of the human lymphatic system led him in 1787 to the publication of *Vasorum lymphaticorum corporis humani historia et ichnographia*, (On the History and Iconography of the Lymphatic Vessels of the Human Body), a work that soon made him famous throughout Europe (2).

The political turmoil that upset the Grand Duchy of Tuscany, with the French occupation in 1799-1800, were trouble for Mascagni's career. Arrested and imprisoned for a period of seven months after the French were expelled, he had to suspend his scientific activity.

Freed from prison by a decree of Ludovico 1st, King of Etruria, Mascagni was appointed a Professor of Anatomy at the University of Pisa in 1801, with the additional charge of lecturing twice a week at the Hospital of Santa Maria Nuova in Florence. Later he was nominated a full Professor at the University of Florence. In Florence, he participated in a project to prepare wax models of all the systems of the human body. These spectacular life size wax models were coordinated under the scientific direction of Felice Fontana and Clemente Susini. They are still preserved in La Specola Museum in Florence.

But the project in which Mascagni was considerably involved for more than fifteen years, until his death, was the preparation of *La Grande Anatomia del Corpo Umano* (The Large Anatomy of the Human Body), published as *Anatomia Universa* (Universal Anatomy), an Atlas with life-size illustrations of the entire human body.

Regrettably, in 1815, Mascagni, died suddenly at the age of 60 of pernicious fever during a stay at his estate of Castelletto, near Siena. His work, which required time and labor, remained unfinished.

Works and Legacy – The family inherited not only plates, drawings, sketches and records, but also debts. To prepare the very large copperplates, drawn by remarkable artists, to have them finely engraved – the costs were exceedingly high and Mascagni had had to mortgage his estate.

Apparently, he had three main plans. The first was *Anatomia per uso degli studiosi di scultura e pittura* (Anatomy for Sculptors and Painters), which appeared posthumously in Florence in 1816, subsidized by Mascagni's brother and grandson (3). This large folio atlas has fifteen finely hand colored illustrations, drawn by Antonio Serantoni (1780-1837), an artist Mascagni had trained and worked with for fourteen years (Figure 1).

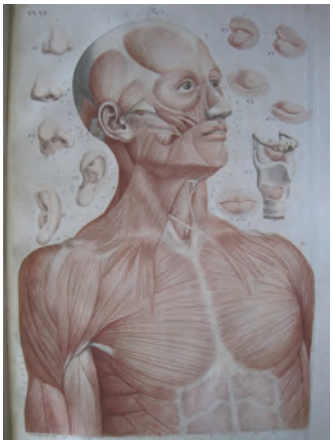

Figure 1 - Mascagni P. The superficial musculature. From Anatomia per uso degli studiosi di pittura e scultura, 1816 (3).

Continued on page 74

The second work was the *Prodromo della grande anatomia* (Prodrome of Large Anatomy), edited by Francesco Antonmarchi and issued in 1819 (4).

The third work, certainly the most spectacular, but also the most complex from a typographical stand point, was the Anatomia Universa (Universal Anatomy), edited by three Professors of Pisa University, and published between 1822 and 1832 (5). It includes forty-four elephant folio hand colored engraved plates representing the different layers of the human body (Figure 2). Antonio Serantoni was the artist who created the plates. Copies were never bound, but stored in a specially designed wooden cabinet. A pirated edition was produced by Francesco Antonmarchi (1780-1838), formerly Mascagni's prosector, who published them in Paris under his own name, between 1823 and 1826, without giving any credit to Mascagni.

Figure 2 - Mascagni P. The venous circulation. From Anatomia Universa 1823 (5).

For his detailed studies on the lymphatics performed in Siena between 1777 and 1781, Mascagni plays a key role in the history of plastic surgery. He conceived an ingenious, new injection technique with mercury, cannulating the lymphatic vessels successively, employing very fine tubular needles, angulated at right angle. In this way, he could demonstrate the pattern of distribution of the entire lymphatic network, to its thinnest branches. This tedious work, never done before, was incredibly tiring and complicated. Mascagni was able to trace the course of the lymphatics in the limbs, lower trunk, head and neck, and lungs, and also the pathway of the superficial and deep lymphatic circulation and their intercommunication. For the first time, he demonstrated the phenomenon of diapedesis, typically accompanying inflammation, the direct connections between lymph and serous vessels, the lack of communication between arteries and veins and, most important, that lymph always passes through one lymphatic station on its way centrally. He named and described almost all the lymphatic glands and vessels of the human body. His studies constituted the basis for future research.

In 1784, he participated in the Paris Academy of Sciences award by submitting the following essay: *"Prodrome d'un ouvrage sur le système des vaisseaux lymphatiques"* (Prodrome on an Essay on the Lymphatic Vessels), accompanied by four plates by Ciro Santi. Due to the poor French language, the work did not receive the prize, but only a special mention for innovative research.

Three years later, in 1787, he published his complete work in a spectacular atlas (Figure 3), the first one on this subject (2) accompanied by 27 in-folio, engraved plates, that depict lymphatic vessels in some of the finest detail present in anatomical illustration, before the advent of radiography or photography. They were drawn by the famous artist, Ciro Santi, a painter and engraver, who moved from his home town of Bologna to Siena to prepare the plates for him. The work, dedicated to Leopold, Grand Duke of Tuscany, is divided into two parts. The first one reviews the history of the lymphatic vessels, whereas the second part shows the distribution of the vessels into different organs and apparatuses. Plates refer to part two only. Plates 1 to 3 explain the anatomy of the lymphatic vessels; plates 4 to 11 demonstrate the superficial and deep circulation of the lower limb; plates 12 to 18 show the lymphatics of the genital area, abdomen and its contents; plates 19 to 21 the thorax and its contents; plate 22 the upper limb, whereas

plate 23 the torso and the neck, plate 24 the superficial circulation of the thorax, head and neck; and finally, plates 25 to 27 the deep lymphatic circulation of the upper limb, head, neck, heart, breast, brain, and tongue. (Figures 4, 5).

The Grand Duke of Tuscany, Leopold of Lorena, so proud of Mascagni's great achievement, doubled his salary.

Nowadays, Mascagni is also remembered for a pathway which eponimically bears his name. It indicates the direct lymphatic route to the supraclavear lymphnodes, bypassing the axilla.

REFERENCES

1. Choulant L. *History and Bibliography of Anatomic Illustration*. Chicago; Chicago University Press, 1920 p. 315
2. Mascagni P. *Vasorum lymphaticorum corporis humani historia et ichnographia*. Siena; Pazzini Carli, 1787
3. Mascagni P. *Anatomia per uso degli studiosi di pittura e scultura*. Firenze; Marenigh, 1816
4. Mascagni P. *Prodromo della grande Anatomia*. Firenze; Marenigh, 1819
5. Mascagni P. *Anatomia Universa*. Pisa; Capurro, 1823-32
6. Mascagni P. *Prodrome d'un ouvrage sur le système des vaisseaux lymphatiques*. Siena; Pazzini Carli, 1784

Figure 3 - Mascagni P. Title page. From Vasorum lymphaticorum . . . , published in 1787 (2).

Figure 4 - Mascagni P. The lymphatics of the head and neck. From Vasorum lymphaticorum... published in 1787 (2).

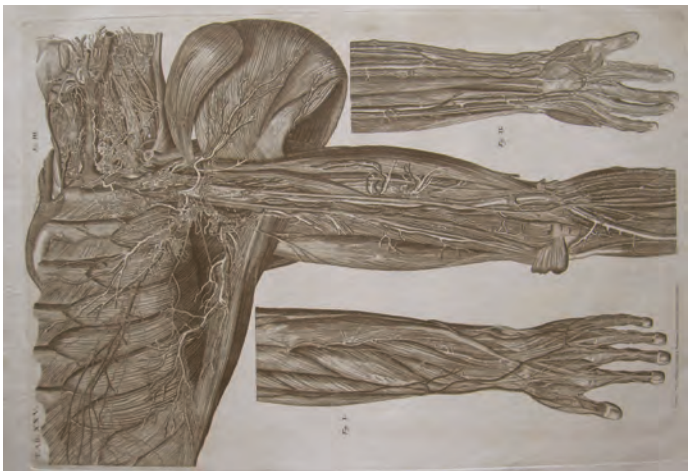

Figure 5 – Mascagni P. The lymphatics of the upper limb and axilla. From Vasorum lymphaticorum... published in 1787 (2).

German Experts in manufacturing **medical devices** for face and body based on **Hyaluronic Acid**

Walsmühler Straße 18, 19073 Dümmer, Germany
Tel: +49 (0) 2602 / 83 868-0, Fax: +49 (0) 2602/ 83 868-20
www.biosciencegmbh.com

Bio | SCIENCE
The Beauty Of Quality

ISAPS WELCOMES NEW MEMBERS

SEPTEMBER 2019 THROUGH FEBRUARY 2020

ARGENTINA
Juan ACHAVAL RODRIGUEZ, MD
Barbara Ligia ALBERNAZ, MD
Facundo ALVARADO BERNARD, MD
Alibeth BAQUERO SUAREZ, MD
Nicolas BIGALLI, MD
Gustavo Horacio BUENADER, MD
Gonzalo CARLES, MD
Guillermo Enrique CONVERNTON, MD
Hernan DIAZ SAUBIDET, MD
Malena FALLET, MD
Lucas Alfredo FERREYRA, MD
Nahuel GONZALEZ CIANI, MD
Rodrigo JUAREZ CALVI, MD
Santiago LOZANO, MD
Fernando MARTINEZ DORR, MD
Emanuel MONTES DE OCA, MD
Leticia Laura NEGRIN UKRAINIEC, MD
Lucas Hugo PARISSO, MD
Polansky PELAEZ HOYOS, MD
Luis PEZZUTTI, MD
Romina Florencia REINO, MD
Jairo Eduardo ROBLEDO MENDEZ, MD
Daniela ROCCA, MD
Jose Adrian ROJAS, MD
Alfredo RUIZ DIAZ SALINAS, MD
Mariano TEJEDOR, MD
Leandro VILA CHEFFER, MD

AUSTRALIA
Iraj AHMADI, MBBS, MS
Patrick TANSLEY, MD

AUSTRIA
Rudolf BARTSCH, MD
Viola EBNER, MD
Franz HAAS, MD
Christoph HARPF, MD
Johannes MATIASEK, MD
Dagmar MILLESI, MD

BANGLADESH
Mohammad MABIN, DSS

BRAZIL
Amro ARIKAT, MBBS
Laura BARROS, MD
Tainara CASSOL, MD
Luiz GAMA, MD
Anne GROTH, MD, PhD
Rolando MENDOZA, MD
Murilo SECANHO, MD
Maurício VIARO, MD

CHINA
Fanfan CHEN, MD
Dongwoo JANG, MD, PhD

COLOMBIA
Gustavo ECHEVERRY, MD
Francisco VILLEGAS, MD

EGYPT
Therese ROMAN, MD
Assem TWAISSI, MBBS

EL SALVADOR
Cesar DUARTE SOSA, MD

FRANCE
Killian ALLEPOT, MD

GEORGIA
Tengiz CHIKVAIDZE, MD

GERMANY
Abbas AHMADLI, MD
Morad AL SHIBLACK, MD, FEPOBRAS
Maria BOYCE, MD
Christian BRATSCHKE, MD
Frederic HECKER, MD
Donya HEINRICH, MD
Wolfgang HOFER, MD
Gunnar HUEBNER, FEBOPRAS
Ramin IPAKTCHI, MD
Alaleh JAMSHIDI, MD
Periklis KARAISKAKIS, MD
Christian LAU, MD
Bernhard MOSER, MD
Peter PANTLEN, MD
Lona RAAB, MD
Mathias REUTEMANN, MD
Hardy SCHWARZE, MD
Iliana STROUTHOU, MD
Dimitrios TAKAS, MD
Hamid Reza TEYMOURI, MD
Karsten WIESSMANN, MD
Christoph ZIMMERMANN, MD, FEBOPRAS

GREECE
Emmanouil KOLAXIDIS, MD

HUNGARY
Gabor MOHOS, MD
Janos VARGA, MD, PhD

INDIA
Ritesh ANAND, MCh
Sandhya BALASUBRAMANYAN, MS, MCh
Sonal BANIPAL, MBBS, MS, MCh
Sharmistha BHATTACHARYYA, MBBS, MS
Smriti BHUSHAN, MBBS, MS, MCh
Jayant DASH, DNB
Deepti GUPTA, MCh
Neha JAIN, MD
Santhy NAIR, MBBS, MRCS
BabuRao RAVURI, MS, MCh
Akangsha SHARMA, MBBS, MS, MCh

INDONESIA
I Made Suka ADNYANA, MD
Ade Sari SITORUS, MD

IRAN
Majid RASTI, MD

IRAQ
Kazim KAKAWAYS, MD

ITALY
Annarita AGOVINO, MD, PhD
Andrea BATTISTINI, MD
Francesco BORELLI, MD
Giulia BOSCAINI, MD
Sara CALABRESE, MD
Vito CAZZATO, MD
Nunzioluca CHIANESE, MD
Massimo CORSO, MD
Giuseppe COTTONE, MD
Giuseppe DEL TORTO, MD
Claudia DI SANTO, MD
Lucio FASCIANI, MD
Valerio FINOCCHI, MD
Andrea FRASCA, MD
Jacopo GALLOTTI, MD
Stefano GENTILESCHI, MD
Andrea GIANNITRAPANI, MD
Ilaria ISAIJA, MD
Stefano MARCELLI, MD
Simone MARRA, MD
Daniele MATTA, MD
Francesco MORI, MD
Andrea PARISI, MD
Tommaso PELLEGATTA, MD
Rosita PENSATO, MD
Raffaella PERELLO, MD
Veronica PONTI, MD
Fabio QUATRA, MD
Vittorio QUERCIA, MD
Francesca RICCARDI, MD
Filippo RIVAROSSA, MD
Andre SALVAL, MD

Lorenzo SECONDI, MD
Tullia Marta TAIDELLI PALMIZI, MD
Sara TANINI, MD
Roberto VALERIANI, MD
Pasquale VEROLINO, MD

JAMAICA
Maria PANZARELLA, MD

JAPAN
Masao BAN, MD

LUXEMBOURG
Arman IVOGHLI, MD

MEXICO
Luis Ulises AGUIRRE GAYOSO, MD
David DE RUNGS BROWN, MD, MHA
Jaime GARCIA ESPINOZA, MD
Carlos HORACIO GARCIA, MD
Eduardo LEON CORONADO, MD

NIGERIA
Egiehiokhin ISIWELE, MBBCh, FMCS, FDAFPRS

PANAMA
Ivan MOSQUERA, MD

PHILIPPINES
Katrina Jo LOBO, MD

POLAND
Mateusz KOZIEJ, MD, PhD
Ryszard MADRY, MD
Jakub MISZCZYK, MD
Joanna WISNIEWSKA-GORYN, PhD
Karolina WOJCICKA, MD

ROMANIA
Adelaida AVINO, MD
Natalia DUMITRESCU, MD
Raluca DUTU, MD
Ioana IONASCU, MD
Paul NISTOR, MD
Alexandru POPA, MD
Claudiu-Andrei POPA, MD
Maria Siramona POPESCU, MD
Timea VIRAG, MD

RUSSIAN FEDERATION
Evgeni BALINER, MD
Elena CHIRIKOVA, MD
Andrey LOKTIONOV, PhD
Timur MELIK, MD
Vasilii POLIAEV, MD
Roman REDIN, MD, PhD

SOUTH KOREA
Dong-Woo JUNG, MD, PhD
Jae Bong KIM, MD, PhD

SPAIN
Francisco BRAVO, MD, PhD
Richard FAKIN, MD
Mauricio UMANA, MD

SWEDEN
Charles RANDQUIST, MD

THAILAND
Chakarin SUCHAKARO, MD

TURKEY
Andaç AYKAN, MD
Mehmet OZDEMIR, MD
Selman TASKIN, MD

UKRAINE
Svetlana RABOTENKO, MD

UNITED ARAB EMIRATES
Zuhair ALFRADAN, FRCSC
Abizer KAPADIA, MCh

UNITED KINGDOM
Saif AL AZZAWI, MChB, MRCS, FRCS
Helena ANTONIADOU, MD
Evgenios EVGENIOU, MBBS, MRCS, FEBOPRAS
David JOHNSON, MA, DM, BM BCh, FRCS
Ajay MAHAJAN, MD, FRCS
Giorgio NETRI, MD
Georgios ORFANIOTIS, MBBS, MRCS, FRCS, EBOPRAS
Omar TILLO, MD, MS, EBOPRAS, FRCS

UNITED STATES
Gary ALTER, MD
Ahad ATTIAH, MBBS
Michael CALOBRACE, MD
Matthew HAGAN, MD
Ali HEIDARI, DO
Robert HOUSER, DO
Tom HUBBARD, MD, FACS
Kristi HUSTAK, MD
Abraham MARCADIS, MD
Tim NEAVIN, MD
Manas NIGAM, MD
John PIERCE, MD
Elan REISIN, MD
Nicolas VILLANUSTRE, MD

MEETINGS CALENDAR

ISAPS COURSE – SOUTH AFRICA

DATES: March 20-22, 2020
LOCATION: Cape Town, SOUTH AFRICA
VENUE: Lord Charles Hotel, Somerset West
CONTACT: Hendrika van der Merwe
TEL: +27-21-981-3081
EMAIL: congress.isaps@eliteconfer.co.za
WEBSITE: http://www.isapscourse.co.za
NOTE: Optional post-course safari to Thornybush Game Lodge, March 23-25. See website for additional information and cost

HIGHLIGHTS OF PLASTIC SURGERY SYMPOSIUM 2020

DATES: March 26-28, 2020
LOCATION: Panama City, PANAMA
VENUE: The Pacific Center Hospital Complex
CONTACT: Mrs. Isqueira Villalaz
TEL: 507-6780-9286 in Spanish – 507-6747-9911 in English
EMAIL: infohighlightsofplasticsurgery@gmail.com
WEBSITE: https://www.highlightsofplasticsurgery.com

ISAPS COURSE – GREECE

Course Postponed to 09 - 11 July 2020
DATES: 09 April – 11 April 2020
VENUE: War Museum www.warmuseum.gr
LOCATION: Athens, GREECE
CONTACT PERSON: Vicky Delidimitriou, vdelidimitriou@noufio.gr
TEL: +30 210–2775219
FAX: +30 210–2714437
WEBSITE: www.isapscourseathens2019.gr
ORGANIZING SECRETERIAT: NOUFIO www.noufio.gr

IPSAC'S 4TH BUTTOCK COURSE

DATES: 16 April – 18 April 2020
LOCATION: Paris, FRANCE
VENUE: Anatomy Lab, Marriott Convention Center
CONTACT: Charlie Pascal
TEL: +33 4 72 83 77 69
EMAIL: charles@ipsac.eu
WEBSITE: http://www.ipsac.eu

BARCELONA RHINOPLASTY 2ND COURSE

Program postponed. New dates are pending.
DATES: 29 April – 02 May 2020
LOCATION: Barcelona, SPAIN
VENUE: Centro Medico Teknon
CONTACT: Silvia Vila
TEL: 34 9 33933 128
EMAIL: svila@vilarovira.com
WEBSITE: http://www.barcelonarhinoplasty.com

ISAPS SYMPOSIUM – SERBIA

Immediately preceding the SRBSAPS Congress – May 8-9
DATE: 07 May 2020
LOCATION: Belgrade, SERBIA
VENUE: Hilton Hotel
CONTACT: Dr. VIoleta Scorobac
TEL: +381-11-244-3152
EMAIL: dr.violeta@dionahospital.com
WEBSITE: https://srbsapscongress.rs

ISAPS F.A.S.T. ADVANCED 2020 – COMPLICATIONS AND DIFFICULT CASE MANAGEMENT

Fast Modules 2 and 3 are combined in this event
DATES: 22 May – 24 May 2020
TOPIC: Breast Advanced
LOCATION: Moscow, RUSSIA
VENUE: Golden Ring Hotel, Smolenskaya str., 5
CONTACT: Anna Pimenova
TEL: +7 (495) 287-46-45
FAX: +7 (495) 287-46-45
EMAIL: orgcom@isapsfast.ru
WEBSITE: www.isapsfast.ru

ISAPS COURSE – RUSSIA

DATES: 28 May – 31 May 2020
LOCATION: St. Petersburg
VENUE: Pribaltiyskaya Park Inn
CONTACT: Igor Bogoroditskiy
EMAIL: i_bogoroditski@yahoo.com
WEBSITE: isapscourse-spb2020.org

15TH BODY LIFT COURSE

DATES: 02 June – 04 June 2020
LOCATION: Geneva, SWITZERLAND
VENUE: Hotel President Wilson
CONTACT: Charles-Henri Pascal
TEL: +33 683 689 907
EMAIL: charles@ipsac.eu
WEBSITE: http://www.ipsac.eu/Courses/Live-Surgery-Course

33RD ANNUAL CONGRESS OF SOFCEP

DATES: 04 June – 06 June 2020
LOCATION: Les Sables d'Olonne, FRANCE
VENUE: Centre de Congres des Atlantes
CONTACT: SOFCEP
TEL: +33(0)53 431 0134
EMAIL: sofcep@vous-et-nous.com
WEBSITE: http://www.chirurgiens-esthetiques-plasticiens.com/congres-sofcep-2/?lang=en

IPSAC LIVE SURGERY COURSE

DATES: 10 June – 12 June 2020
LOCATION: Lyon, FRANCE
VENUE: Hotel Marriott Lyon and Clinique du Parc
CONTACT: Charles-Henri Pascal
TEL: +33 683 689 907
EMAIL: charles@ipsac.eu
WEBSITE: http://www.ipsac.eu/Courses/Live-Surgery-Course

18TH BERLIN INTERNATIONAL BEAULI™ SYMPOSIUM – FAT GRAFT AND STEM CELLS

DATES: 12 June – 13 June 2020
LOCATION: Berlin, GERMANY
VENUE: Park-Klinik Birkenwerder Fachklinik für Plastische und Ästhetische Chirurgie
CONTACT: Wibke Budensiek
TEL: +49 3303 513 4000 0
EMAIL: info@beauli.de
WEBSITE: http://www.park-klinik-birkenwerder.de

15TH INTERNATIONAL FRESH CADAVER COURSE ON FACELIFT AND PERI-ORBITAL PROCEDURES

DATES: 12 June – 13 June 2020
LOCATION: Utrecht, NETHERLANDS
VENUE: Medical University
CONTACT: Jacques van der Meulen
TEL: +31 641 461 496
EMAIL: drvdMeulen@gmail.com
WEBSITE: http://www.drtulp.nl

ISAPS COURSE – SPAIN

DATES: 18 June – 20 June 2020
LOCATION: Marbella, SPAIN
VENUE: H10 Andalucia Plaza Hotel
CONTACT: Vanessa Garcia
TEL: +34-653-503-549
FAX: +34-952-868-827
EMAIL: info@mipss.eu
WEBSITE: www.isapscourse.es

ISAPS SYMPOSIUM – GEORGIA

DATE: 03 July 2020
LOCATION: Tbilisi, GEORGIA
VENUE: The Biltmore Tbilisi Hotel, 29 Shota Rustaveli Ave, Tbilisi
CONTACT: Mariam Tsivtsivadze
TEL: +995 322 420 420
EMAIL: hello@kolkhida.org
WEBSITE: www.kolkhida.org

ISAPS COURSE – GREECE

Course postponed from April 9-11
DATES: 09 July - 11 July 2020
LOCATION: Athens, Greece
VENUE: Radisson Blu Park Hotel
CONTACT PERSON: Vicky Delidimitriou, vdelidimitriou@noufio.gr
TEL: +30 210 – 2775219
FAX:+30 210 – 2714437
WEBSITE: www.isapscourseathens2020.gr
ORGANIZING SECRETARIAT: NOUFIO WWW.NOUFIO.GR

ISAPS SYMPOSIUM – CHILE

DATES: 07 August – 08 August 2020
LOCATION: Santiago, CHILE
VENUE: Hotel Plaza El Bosque Nueva Las Condes
CONTACT: Dr. Montserrat Fontbona
TEL: 56-226-320-714
EMAIL: soccpchile@gmail.com
WEBSITE: www.sccp.cl

SECONDARY OPTIMIZING AESTHETIC SURGERY SYMPOSIUM (SOS) 2020

DATES: 31 August – 01 September 2020
LOCATION: Vienna, AUSTRIA
VENUE: Andaz Belvedere Vienna Hotel
CONTACT: Barbara Boeld
TEL: +49-89-18-90460
EMAIL: congress@bb-mc.com
WEBSITE: http://www.sos2020.eu

25TH WORLD CONGRESS

25th Congress of ISAPS – 50th Anniversary Celebration
DATES: 02 September – 05 September 2020
LOCATION: Vienna, AUSTRIA
VENUE: Austria Center Vienna
CONTACT: Barbara Boeld
TEL: +49-89-18-90460
EMAIL: congress@bb-mc.com
WEBSITE: www.isapsvienna2020.com

ISAPS COURSE – HUNGARY

DATES: 29 October – 31 October 2020
LOCATION: Debrecen, HUNGARY
VENUE: Kölcsey Convention Center Debrecen
CONTACT: Dr. Csaba Molnár
TEL: (+361) 299 0184
EMAIL: convention@convention.hu
WEBSITE: Pending

GLOBAL AESTHETICS 2020

DATES: 05 November – 08 November 2020
LOCATION: South Beach, Miami, Florida, USA
VENUE: Loews Miami Beach Hotel
TEL: US Toll free: 1-859-202-3801
EMAIL: dee@gaconference.com
WEBSITE: https://globalaestheticsconference.com/

TD ABS, THE MEETING

DATES: 06 November – 08 November 2020
LOCATION: Bogota, COLOMBIA
VENUE: Estelar Hotel & Convention Center, Cartagena
CONTACT: Johana Poveda/Commercial Director
TEL: +57 310 262 8693
EMAIL: info@tdabsmeeting.com or johana@alfredohoyos.com
WEBSITE: https://tdabsmeeting.com

ISAPS F.A.S.T. ADVANCED 2020 – COMPLICATIONS AND DIFFICULT CASE MANAGEMENT

DATES: 20 November – 22 November 2020
TOPIC: Body Advanced
LOCATION: Moscow, RUSSIA
VENUE: Golden Ring Hotel, Smolenskaya str., 5
CONTACT: Anna Pimenova
TEL: +7 (495) 287-46-45
FAX: +7 (495) 287-46-45
EMAIL: orgcom@isapsfast.ru
WEBSITE: www.isapsfast.ru

ISAPS COURSE – INDIA

ISAPS.AESURG 2021
DATES: 09 February – 13 February 2021
LOCATION: Urajkund, Delhi NCR, INDIA
VENUE: Taj Vivanta
CONTACT: Dr. Rakesh Kalra
TEL: +91 9760077000
EMAIL: isaps.aesurg2021@gmail.com
WEBSITE: www.aesurg2021.com

ISAPS EXECUTIVE OFFICE STAFF

45 Lyme Road, Suite 304
Hanover, NH, USA 03755
Phone: 1-603-643-2325
Fax: 1-603-643-1444
Email: ISAPS@isaps.org
Website: www.isaps.org

EXECUTIVE DIRECTOR
Catherine Foss
ISAPS@isaps.org

GRAPHIC DESIGNER
Jodie LeBrun
Abstracts@isaps.org

FINANCE OFFICER
Sean Finnell
Accounting@isaps.org

EDUCATION EVENTS MANAGER
Michele Nilsson, CMP
Registrar@isaps.org

ISAPS NEWS MANAGEMENT

EDITOR-IN-CHIEF
Nina Naidu, MD (United States)

ASSOCIATE EDITOR, HISTORY OF MEDICINE
Riccardo Mazzola, MD (Italy)

MANAGING EDITOR
Catherine B. Foss (United States)

CHAIR, COMMUNICATIONS COMMITTEE
Tim Papadopoulos, MD (Australia)

EMERITUS EDITOR
J. Peter Rubin, MD, FACS (United States)

ISAPS BOARD OF DIRECTORS, COMMITTEE CHAIRS & APPOINTMENTS 2018 – 2020

Board of Directors

President	Dirk Richter, Germany
President-Elect	Nazim Cerkes, Turkey
1st Vice President	Lina Triana, Colombia
2nd Vice President	Gianluca Campiglio, Italy
3rd Vice President	Arturo Ramirez-Montanana, Mexico
Secretary	Ivar van Heijningen, Belgium
Treasurer	Kai Schlaudraff, Switzerland
Historian	Peter Scott, South Africa
Parliamentarian	Tim Papadopoulos, Australia
National Secretaries Chair	Michel Rouif, France
Education Council (EC) Chair	Vakis Kontoes, Greece
EC Vice-Chair	Ozan Sozer, USA
Past President	Renato Saltz, USA
Trustee	Nina Naidu, USA
Trustee	Fabian Cortinas, Argentina
Executive Director	Catherine Foss, USA

Standing Committee Chairs

Executive	Dirk Richter, Germany
Nominating	Renato Saltz, USA
Membership	Fabian Cortinas, Argentina
By-Laws	Tom Davis, USA
Communications/Branding/Marketing	Tim Papadopoulos, Australia
Patient Safety	Foad Nahai, USA
Journal Operations	Nazim Cerkes, Turkey
Finance & Investment	Kai Schlaudraff, Switzerland
Newsletter	Nina Naidu, USA
Residents & Fellows	Maria Wiedner, Germany
Women Plastic Surgeons	Teresa de la Cerda, Chile

Education Council

Vakis Kontoes, Greece – Chair
Ozan Sozer, USA – Vice Chair

Ad Hoc Committee Chairs

Humanitarian	Tunc Tiryaki, Turkey & Nina Naidu, USA
Industry Relations	Kai Schlaudraff, Switzerland
Insurance	Nigel Mercer, United Kingdom
Global Survey	Dennis von Heimburg, Germany
Global Accreditation	Ozan Sozer, USA & Ivar van Heijningen, Belgium
Visiting Professor	Renato Saltz, USA
Global Alliance	Mark Jewell, USA
Continental Communication	Andre Cervantes, Brazil
New Talents	Al Aly, UAE
50th Anniversary	Joe Hunstad, USA
Patient Education	Stefano Danilla, Chile
Social Media	Simone Hellmann, Germany
Webinar	Nazim Cerkes, Turkey
E-Learning Development	Gianluca Campiglio, Italy
International Board Examination	Daniel Kalbermatten, Switzerland

DISCLAIMER:
ISAPS News is not responsible for facts, opinions, and other information presented by the authors or advertisers in this newsletter or otherwise. This newsletter presents current scientific information and opinions pertinent to medical professionals. It does not provide advice concerning specific diagnosis and treatment of individual cases and is not intended for use by the layperson. Readers are strongly advised to confirm that the facts, opinions, and other information comply with the latest legislation and standards of practice. ISAPS, the editors, the authors, and the publisher will not be responsible for any errors or liable for actions taken as a result of facts, opinions, and other information expressed in this newsletter or otherwise. Copyright © 2020 by the International Society of Aesthetic Plastic Surgery, Inc. All rights reserved. Contents may not be reproduced in whole or in part without written permission of ISAPS.

Quality you can feel
Commitment you can feel
Partnership you can feel



Proven Performance

POLYTECH Health & Aesthetics GmbH
Altheimer Str. 32 I 64807 Dieburg I Germany
www.polytechhealth.com

POLYTECH

Made in Germany

MERZ AESTHETICS®

YOUR PRIORITY

YOUR PATIENTS

YOUR SUCCESS IS OUR SUCCESS

You're listening to patients. We're listening to you. We continually strive to introduce new products and services to support you in addressing a full range of patient and practice needs for the face, neck, décolletage, hands and more.

Learn more at MerzUSA.com.

YOUR PRACTICE

MERZ

Copyright © 2018 Merz North America, Inc.
The Merz® Logo and the Merz Aesthetics® logo are registered trademarks of Merz Pharma GmbH & Co. KGaA.
ML02518-00

INTERNATIONAL SOCIETY OF AESTHETIC PLASTIC SURGERY

SEPTEMBER 2 – 5, 2020
VIENNA, AUSTRIA

WELCOME TO VIENNA, THE MOST LIVEABLE CITY IN THE WORLD

A young and vibrant city – full of historical buildings, culture and hip restaurants! The ideal place to learn from the Best in the World of aesthetics, to reconnect with your international friends, or simply to enjoy Austrian hospitality. There is no better place to celebrate our 50th anniversary.

www.isapsvienna2020.com

HOT TOPICS

- Live Surgery on Complication Cases (SOS)
- Aesthetic Dissection Cadaver courses
- Live Marking sessions
- Best and Worst Case session
- Problems and Solutions panels
- HD Liposuction panels
- Best of the World competition
- Reboot your practice
- The difficult neck
- BIA-ALCL update
- Safe Gluteal Fat Grafting
- Live demo injections
- Social media training